

Consensus on Wound Antisepsis: Update 2018

Axel Kramer^a Joachim Dissemond^c Simon Kim^b Christian Willy^d
Dieter Mayer^e Roald Papke^a Felix Tuchmann^f Ojan Assadian^g

^aInstitute of Hygiene and Environmental Medicine and ^bDepartment of Trauma, Reconstructive Surgery and Rehabilitation Medicine, University Medicine Greifswald, Greifswald, ^cDepartment of Dermatology, Venerology and Allergology, University Hospital Essen, Essen, and ^dDepartment of Trauma Surgery, Orthopedics, Reconstructive, Plastic and Hand Surgery, Bundeswehr Hospital, Berlin, Germany; ^eDepartment of Surgery, Kantonsspital Freiburg, Freiburg, Switzerland; ^fDepartment of Dermatology and ^gDepartment of Infection Control and Hospital Epidemiology, Medical University of Vienna, Vienna General Hospital, Vienna, Austria

Keywords

Wound antisepsis · Wounds-at-Risk Score · Antiseptics · Drug · Medical device · Octenidine · Polihexanide · Hypochlorite · Iodophors · Taurolidine · Silver ions · Acetic acid · Negative pressure wound therapy with the instillation of antiseptics · Physical body warm atmospheric plasma · Silver sulfadiazine · Dyes · Mercury compounds · Hydrogen peroxide

Abstract

Wound antisepsis has undergone a renaissance due to the introduction of highly effective wound-compatible antimicrobial agents and the spread of multidrug-resistant organisms (MDROs). However, a strict indication must be set for the application of these agents. An infected or critically colonized wound must be treated antiseptically. In addition, systemic antibiotic therapy is required in case the infection spreads. If applied preventively, the Wounds-at-Risk Score allows an assessment of the risk for infection and thus appropriateness of the indication. The content of this updated consensus recommendation still largely consists of discussing properties of octenidine dihydrochloride (OCT), polihexanide, and iodophores. The evaluations of hypochlorite,

taurolidine, and silver ions have been updated. For critically colonized and infected chronic wounds as well as for burns, polihexanide is classified as the active agent of choice. The combination 0.1% OCT/phenoxyethanol (PE) solution is suitable for acute, contaminated, and traumatic wounds, including MRSA-colonized wounds due to its deep action. For chronic wounds, preparations with 0.05% OCT are preferable. For bite, stab/puncture, and gunshot wounds, polyvinylpyrrolidone (PVP)-iodine is the first choice, while polihexanide and hypochlorite are superior to PVP-iodine for the treatment of contaminated acute and chronic wounds. For the decolonization of wounds colonized or infected with MDROs, the combination of OCT/PE is preferred. For peritoneal rinsing or rinsing of other cavities with a lack of drainage potential as well as the risk of central nervous system exposure, hypochlorite is the superior active agent. Silver-sulfadiazine is classified as dispensable, while dyes, organic mercury compounds, and hydrogen peroxide alone are classified as obsolete. As promising prospects, acetic acid, the combination of negative pressure wound therapy with the instillation of antiseptics (NPWTi), and cold atmospheric plasma are also subjects of this assessment.

© 2017 S. Karger AG, Basel

Renaissance of Xenobiotic Wound Antiseptics

Wound antiseptics lost some of their importance for more than a century due to the toxicity of Lister's carbolic wound spray, the toxic side effects of the next generation of antiseptics such as mercury- or arsenic-based compounds, and the initial euphoria after the introduction of the antibiotic penicillin G. Reasons for the renaissance of antiseptics are the development of effective and well-tolerated antiseptic substances, the pandemic spread of multidrug resistant organisms (MDROs), a comparatively high rate of sensitization to locally applied antibiotics, the microbicidal instead of microbiostatic effect of antiseptics, the locally delimited effect with no or – in the case of polyvinylpyrrolidone-iodine (PVP-I) – few systemic consequences when correctly applied considering contraindications, and last but not least, the absence of resistance development for those antiseptic agents which damage pathogens irreversibly. For example, so far, no resistance has been observed against antiseptics with unspecific effects, such as the destruction of the bacterial cell as a whole, or the inhibition of its function with destruction of the cell membrane or blockage of negative surface charges. This is the case for octenidine dihydrochloride (OCT), polihexanide (PHMB), PVP-I, and oxidizing agents, such as hypochlorous acid, or active substances from the class of peroxides/peroxy acids, such as hydrogen peroxide (H₂O₂). Microbiostatic antiseptics, however, show transferable resistances, and can be partially cross-resistant with certain antibiotics. Examples are the activation of efflux pumps [1, 2] for chlorhexidine digluconate (CHD) and quaternary ammonium compounds, and a genetically coded periplasmic Ag(I)-binding protein and 2 efflux pumps for silver ions [3]. This is also true for topically applied antibiotics such as mupirocin [4], silver sulfadiazine [5–7], neomycin, and bacitracin [8], which have all lost their significance as wound antiseptics, except for mupirocin [9], which is still used for the decolonization of MRSA (methicillin-resistant *Staphylococcus aureus*). Especially the over-the-counter sale (without prescription) of mupirocin as a wound antiseptic is considered to be a major cause for the increase in resistance development [5, 10], which can locally exceed more than 20% of examined hospital-associated MRSA strains [11].

The local application of antibiotics for locally confined wound infections and colonization is to be avoided, not only because of the promotion of resistance development, but also because of their microbiostatic mode of action and concentrations that are hard to adjust. Any systemic escalation of the infection, such as positive blood cultures, must be treated with systemic antibiotics in combination with topic antiseptics, if necessary.

Table 1. MIC (µg/mL) at 24 h exposure of selected antibiotics and antiseptics against microbial test strains

Microbial strain	Cefuroxime [269, 270]	OCT [50]	PHMB [50]
<i>S. aureus</i>	0.5 to 64	2	0.5
MRSA	16	1	0.5
<i>E. faecalis</i>	2 to 128	1	2
VRE	–	4	4
<i>E. coli</i>	8 to >400	8	0.5
<i>P. aeruginosa</i>	>400	8	2
<i>C. albicans</i>	–	1	1

Since the microbicidal effect of antibiotics can only be examined in a suspension test and has thus seldom been the focus of studies, only a few published reports on minimal inhibitory concentration (MIC) exist which could serve as a basis for comparison. Nevertheless, this literature shows that many antiseptics are vastly more effective compared to antibiotics (Table 1). For gentamicin, which is also approved for topical use as a cream, the MIC for sensitive *S. aureus* was 0.5–1 µg/mL, for *Pseudomonas aeruginosa* 2 µg/mL [12], and for Enterobacteriaceae 25–75 µg/mL [13]. In contrast, for fluoroquinolones for example, the MIC against sensitive *Escherichia coli* is 0.008–0.02 µg/mL, which is much lower than for OCT or PHMB, where the MIC may be up to 1,000 µg/mL for resistant strains [14]. The use of this antibiotic would not be recommendable.

The German Society for Wound Healing and Wound Treatment (Deutsche Gesellschaft für Wundheilung und Wundbehandlung) only recommends microbiological diagnostics for chronic wounds if there are signs of a systemic infectious event originating from the wound area [15]. For this reason, the local application of antibiotics used for the treatment of systemic infections should be avoided in order to circumvent the development of resistance and sensitization [16]. The WHO also does not recommend topical use of or rinsing with antibiotics in this case [17] (Table 1).

Evidence Regarding Wound Antiseptics

An infected or critically colonized wound must be microbiologically remediated in order to heal properly [18–20]. It must be determined whether the topical use of antiseptics is sufficient or if a systemic antibiotics is necessary due to septic spreading. If a wound is at risk of becoming infected, antiseptics can prevent the emergence of infection [21].

Although the proper treatment of wounds has been a challenge since the beginning of mankind, sufficient evidence is lacking for the choice of antiseptics to prevent wound infections as well as treat wounds, especially chronic ones. Many dermatological patients suffer from different types of erosive skin lesions, e.g., follicular bacterial infections [22, 23] or eczema [24]. Often, local antibiotics are used instead of considering antiseptic options for treatment, although according to expert opinion, the latter are more effective and do not pose a risk of resistance development [22]. This leads to the conclusion that further studies and observations must be undertaken to examine the potential of antiseptic treatment for these conditions. Since only a small number of clinical trials are available as the basis for decisions, all available results from studies ranging from *in vitro* experiments up to clinical studies, including meta-analyses, must be collected to form a plausible synopsis [18]. For this reason, all clinical studies available in PubMed were taken into account for Tables 6–9, regardless of the evidence level.

Classification of Compounds for Wound Antisepsis

Products declared as wound antiseptics are classified as pharmacological drugs (PDs). If the mechanical effects such as rinsing (solutions) or absorption (gauzes) are the primary mode of action and the antiseptic effect is only provided by the addition of preservatives, the product is classified as a medical device (MD). The distinction from PDs is based on the primary mode of action and the intention for use as described by the manufacturer. PDs act pharmacologically, metabolically, and/or immunologically, while MDs primarily act physically. The pharmacological mode of action can take various manifestations:

- The binding to adhesion proteins or their biochemical or immunological destruction can inhibit or prevent the attachment of bacteria [25, 26]. As long as pathogens residing and multiplying in the upper cell layers are killed, the effect is considered pharmacological, since reproduction cannot take place without adhesion on receptors and interaction with the tissue.
- Wound healing can be supported by biochemical means, such as interaction with inflammation mediators. This was observed for PVP-I [27], OCT [28], and hypochlorous acid [29].
- Healing can also be supported for aseptic wounds. This was observed for liposomal PVP-I [30] and PHMB [31, 32], although the exact mechanism has yet to be explained.

It is always considered to be a pharmacological mode of action if wound healing is supported by the antiseptic effects on cell-adherent pathogens, possibly with associated biochemical or immunological consecutive reactions. This is also true if the active substance binds to the wound tissue and offers a so-called remanent effect by gradual release [33, 34]. If the main mode of action of wound rinsing solutions or wound dressings is based on physical means, e.g., rinsing, absorption, moisture regulation, or irreversible physicochemical binding of microorganisms, they are classified as MDs. In practice, the transition between MPs and MDs is fluid, since physical and pharmacological modes of actions cannot be strictly separated. Since the classification does bear consequences for pharmacological-toxicological and clinical testing as well as user protection, the correct classification is important in terms of ethics and reimbursement. This demarcation is further complicated by the approval of some antiseptics such as PHMB as a preservative in antiseptically effective concentrations and their use in wound treatment preparations without further declaration [33, 34]. Because of this, all comparisons made within this consensus recommendation require further careful evaluation and interpretation.

Indications

The use of antiseptics for prophylactic or therapeutic indications in wound treatment is possible for the following objectives:

- Prevention of infection of acute wounds, e.g., after trauma, bite, or gunshot wounds
- Prevention of postsurgical wound infections (surgical site infections; SSI)
- Decolonization of wounds colonized with MDRO
- Treatment of clinically manifested wound infections, including so-called critical colonization
- Preparation for debridement or wound cleaning of chronic wounds in outpatient facilities

The interaction between microorganisms and wounds can take place on different levels (Table 2). The clinically characterized term “critical colonization” reflects the hard to define condition of the transition between physiological wound colonization and the pathological condition of a manifest local infection [35].

Although almost all wounds, especially chronic ones, are contaminated, not all patients develop an infection. Since physiological colonization is either irrelevant or – due to colonization resistance – even beneficial for the process of wound healing [36], the Wounds-at-Risk (WAR) Score [37], which is the sum of different points,

Table 2. Classification of the microbial status of wounds

Term	Characteristics
Contamination	Microorganisms are present and have attached to the tissue (microbial attachment) without (initial) proliferation
Colonization	Microorganisms are present and are proliferating; a clinically significant immunological host reaction is (initially) absent
Critical colonization	Microbial proliferation without the formation of classical signs of infection but delayed wound healing due to toxin production/or the wound is colonized with antibiotic resistant strains without signs and symptoms of infection
Local infection	Clinically observable, immunological host reaction with the typical signs of infection including redness (erythema 1–2 cm measured from the wound margin) with tendencies of increase could be equivalent to spreading infection with the risk of generalization, swelling, increased local skin/tissue temperature, pain, functional impairment, and increase in exudate quantity and viscosity, for example, perceptible odor and stagnation in wound healing
Systemic infection	In addition to the local inflammatory reactions, signs of a systemic host reaction such as leukocytosis, increase in C-reactive protein and fever

was introduced in order to evaluate the infection risk (Table 3).

If the WAR Score reaches or exceeds 3 points, an antiseptic treatment is justified.

Criteria for Choosing Antiseptic Agents

Efficacy

When treating acute wounds, a microbicidal effect and broad spectrum of activity are desirable. Only in certain cases does the substance have to be virucidal and additionally effective against bacterial spores. For chronic wounds, the spectrum of activity must only encompass Gram-positive and Gram-negative bacteria if no special circumstances have been diagnosed. There should be no risk for the development of resistance, especially cross-resistance towards antibiotics.

The efficacy of antiseptics is expected to result in killing of test organisms $\geq 3 \log_{10}$ [38, 39] for a typical type of organic load within the declared exposure time.

In some cases, the efficacy is additionally tested without an organic load typical for wounds, although this does not correspond to the application situation, unless the load is significantly reduced, for example by repeated rinsing. Without an organic load, the efficacy is expected to be $\geq 5 \log_{10}$ versus bacteria and $\geq 4 \log_{10}$ versus *Candida albicans* [38].

Tolerability

The tolerability of antiseptics in wounds is supposed to be equal to Ringer solution, physiological saline, or an inert hydrogel. Ideally, wound healing is promoted.

A good point of orientation would be to follow the practical approach of not applying anything to chronic wounds which should not be applied to the eyes. This is true for PVP-I up to 5% and for PHMB up to 0.02% [40–42], but not for silver sulfadiazine, CHD, or OCT (0.1%). If adjacent tissues can be exposed in the wound treatment, such as cartilage, central nervous system (CNS), or peritoneum, the compatibility must be clarified. Furthermore, sensitization potential including anaphylaxis risk should be low or absent; there should also be no risk of long-term adverse effects such as mutagenicity, carcinogenicity, or teratogenicity. If the quotient of bactericidal efficacy and tolerability against mouse fibroblasts in vitro, both tested under the same conditions, is >1 , the tolerance for the antiseptic of eukaryotic cells is better than that of bacteria. This is true for OCT, PHMB, and almost for PVP-I (Table 4). A detailed observation about the selective antiseptic effect can be made when, in cocultures of human cells and bacteria, the prokaryotic cells are destroyed, while the eukaryotic cells survive, or bacteria in a comparable solution are killed without damage to human cells. This is demonstrated for sodium hypochlorite (NaOCl) [43], PHMB [44], and PVP-I [45]. Analogously, the treatment of epidermis equivalents

Table 3. Assessment of risk for wound infection [37]

Risk class	Risk condition (based on risk status and different indications)	Point score
1	Acquired immunosuppressive disease (e.g., diabetes mellitus) Acquired immune defect due to medical therapy such as cyclosporine, methotrexate, glucocorticoids, or antibodies Solid tumor disease Systemic hematological disease Postsurgical wound healing disorder, which results in (unplanned) secondary healing Potentially heavily contaminated wounds (e.g., perineum, genitals) Problematic hygienic conditions related to social or occupational environment (e.g., agriculture, lorry driver) Patient age >80 years Young age of patient (premature infants, babies, infants) Wounds persisting for >1 year Wound dimensions of >10 cm ² Chronic wounds of any etiology having a depth of >1.5 cm Extended inpatient status >3 weeks	Per risk 1 point
2	Severe acquired immune defects (e.g., HIV infection) Heavily contaminated acute wounds Bite, stab, and gunshot wounds penetrating 1.5–3.5 cm	Per risk 2 points
3	Severe innate immunodeficiency such as Wiskott-Aldrich, Di-George syndrome, immunodeficiency after stem cell transplantation, AIDS, immunosuppressive therapy [271] Burn wounds with involvement of >15% BSA Traumatically contaminated wound after debridement Wounds that have a direct connection to organs or functional structures (e.g., including joints) or which contain foreign material Bite, stab, and gunshot wounds penetrating >3.5 cm	Per risk 3 points

derived from human keratinocytes with OCT alone or in combination with test organisms demonstrated no cytotoxic effect in viable keratinocytes [51]. In contrast, H₂O₂ inhibits mammalian cells beginning with a concentration of 8.5 mg/L [46], thus inhibiting fibroblasts, whereas bacteria still survive [47]. However, this is not transferable to the endogenous formation of H₂O₂ occurring in the context of the nonspecific immune response, for example by granulocytes. Thus, 0.003% H₂O₂ already inhibits the cytolytic activity of natural killer cells, but the killer cells remain vital [48]. Even if, for example, H₂O₂ is formed in noncytotoxic concentrations in medical honey by glucose oxidase, this is not comparable with the external antiseptic application of pure H₂O₂ alone [49].

In acute wounds the fast-acting effect of the antiseptic is at the forefront, under certain circumstances with a necessary depth effect, for example in patients with bite, puncture, or gunshot injuries. For chronic wounds, a longer exposure time is acceptable for reaching the antiseptic effect due to repeated application and/or remaining on the wound. Wound healing should also be promoted here.

Table 4. Biocompatibility index as a quotient of IC₅₀ for L929 cells and the required MIC for a reduction factor of ≥3 log₁₀ [173]

Compound	<i>E. coli</i>	<i>S. aureus</i>
OCT	1.7	2.1
PHMB	1.5	1.4
PVP-I (aqueous solution, referring on I ₂)	0.9	1.0
CHD	0.7	0.7
Triclosan	0.2	0.5
Ag-protein (referring Ag ⁺)	0.2	0.1
Ag(I)-sulfadiazine and silver nitrate	not measurable	

Taking into account the different properties of antiseptic active ingredients (Table 5), the following development trends are apparent. PVP-I has partly lost importance due to the introduction of more recent and advanced substances. By solving the stability problem, the combination of sodium hypochlorite/hypochlorous acid

Table 5. Properties of wound antiseptics relevant for antimicrobial agents used on wounds

Compound	Antimicrobial onset time	Deep effect ^b	Development of resistance	Wound healing	Cartilage tolerability	Sensibilization	Systemic risk
Ag ⁺	≥24 h ^a [272]	3	Yes	Inhibition [191, 192]	?	No	Yes [273]
CHD	3–10 h ^a [43]	1		No inhibition [274]	No	Yes (rare), anaphylaxis (n >200)	? ^e
AA	15–30 s [49]	2	No	At 0.15% supportive [229, 275, 276]	?	No	No
OCl ⁻	30 s to 5 min ^c [277]	2		Supportive [278]	?		
OCT	3–10 h ^a [39]	1 ^d		No inhibition [30, 36]	No [279]	No	
PHMB	3–10 h ^a [39]	2		Supportive [94]	≤0.005% [279]	Yes (rare), anaphylaxis (n = 3)	
PVP-I	30 min ^a [39]	3		Partial inhibition [172]	Yes [279]	Yes	Yes

1, superficial effect due to high protein binding; 2, shallow penetration depth; 3, larger than 2.

^a Test-carrier (Tc) with organic load [39, 272]. ^b Due to a lack of experimental data, theoretical extrapolation based on physicochemical properties or demonstrated absorption. ^c Without load. ^d In combination with phenoxyethanol 2 or 3. ^e Possibility of separation of 4-chloraniline from the chlorhexidine molecule [76].

(HOCl/OCl⁻) or sodium hypochlorite (NaOCl) is available as an additional option. Acetic acid (AA) or combinations with fruit acids such as lactic, malic, citric, fumaric, or oxalic acid are gaining increasing interest, in particular due to their efficacy against *P. aeruginosa* and the promotion of wound healing, but also due to their availability in countries with limited resources.

Properties of Selected Antiseptic Active Agents

Iodophores and modern compounds such as OCT, PHMB, and stabilized hypochlorite meet the requirements for antiseptic activity in vitro. Remanent effects are displayed only by OCT, PHMB, and CHD. Wound healing is enhanced by PHMB, hypochlorite, and AA depending on the concentration. For PVP-I there is an increased risk of sensitization as well as absorptive side effects, particularly in thyroid disorders.

Octenidine

In vitro and Animal Experiments

OCT shows superior efficacy [50] in the quantitative suspension test without protein load compared with PVP-

I, PHMB, and CHD [51]. In relation to cytotoxicity, OCT is superior to PVP-I [52, 53]. When tested on metal carriers under load (artificial wound fluid), PVP-I solution was effective within in a time frame of 5 min, whereas gels based on OCT (0.05%) or PHMB (0.04 or 0.02%) needed 30 min or 3 h (PHMB 0.02%) to take effect [39]. PVP-I was also most effective in an in vitro wound model with *S. aureus*, followed by OCT and PHMB [54]. However, OCT showed superior efficacy in a biofilm model with *P. aeruginosa* PVP-I [55]. The *S. aureus* biofilm was almost completely eliminated within 5 min [56]. Even in experimental burns in rats, OCT significantly exceeded both PHMB and PVP-I tested against *P. aeruginosa* [57]. CHD interacts antagonistically with gentamicin and synergistically with OCT [58]. In vitro, phagocytosis and growth factors, such as the platelet-derived growth factor, are stimulated by OCT [59], which can be beneficial for wound healing.

Side Effects

When OCT/phenoxyethanol (PE) was used in the epicutaneous patch test, a negative response was found for OCT, while a positive response to PE and cocamidopropyl betaine was detectable. However, the distinction between allergic and irritating reactions was inconclusive

Table 6. Summary of clinical study findings for OCT

Type of wound	Comparison	Result	Study design	Sample size, <i>n</i>	Year
VLU	W vs. W with OCT vs. OCT wound gel, no difference in infection rate at beginning	Wound healing and time to heal was significantly better in both OCT study arms, lowest costs in wound-gel study section	Prospective open-label cohort study	17/17/15	2016 [280]
VLU	W with OCT vs. W with silver	OCT showed significantly rapid healing and reduction of pain, microbial eradication after 28 and 50 days	RCT	40/40	2015 [281]
Neoplastic ulcer	OCT-soaked W; comparison baseline vs. after 3 weeks of treatment	Significantly faster wound healing, significant eradication of potentially pathogenic Gram-positive and Gram-negative bacteria, no adverse events	Prospective observational study	30	2013 [282]
Split-skin harvest sites	OCT-hydrogel vs. hydrogel sites	Significant reduction of wound colonization, no difference in time to heal	Double-blind RCT	31/30	2012 [36]
VLU	OCT/PE vs. Ringer lactate solution	No difference in time to heal; for OCT fewer adverse events	Double-blind RCT	60/66	2012 [283]
Second-degree burn	Irrigation of wound with OCT/PE, thereafter OCT gel vs. silver sulfadiazine	Significant reduction of pain in OCT study arm, tendentially improved wound healing; possibly no difference observable due to initial OCT treatment in both study sections	Prospective RCT, contralateral site served as control	30/30	2011 [284]
Musculoskeletal infection	OCT irrigation and drainage + OCT-soaked gauze	After 5–24 days eradication of all pathogens, no adverse events	Prospective observational study	8	2010 [285]
Neoplastic ulcer	OCT/PE-soaked gauze; comparison of baseline vs. after 3 weeks of treatment	Eradication of <i>S. epidermidis</i> and <i>P. aeruginosa</i> , reduction of necrosis, exudate, erythema, and edema; 1× persistence of <i>P. aeruginosa</i> , 1× persistence of <i>E. coli</i> , and 2× persistence of <i>E. faecalis</i>	Prospective observational study	16	2008 [286]

VLU, venous leg ulcer; W, wound dressing.

[60]. On the basis of the low absorption determined only after removal of the upper skin barrier, no systemic absorption is to be expected when applied to wounds [61].

Clinical Studies

OCT is available as a solution and a gel. The antiseptic (OCT/PE) itself as well as the rinse and the gel are well tolerated, as shown by studies (Table 6) and case reports [62–64]. As an MD (rinse), it is suitable for wound cleansing [62] and supports biofilm removal [59]. Especially the gel

is particularly suitable for antiseptics in patients with burn injuries. OCT is superior to silver and PVP-I in the latter case (Table 6). In the surgical treatment of traumatic amputation and splinter injuries which were colonized with MDRO, an antibiotic treatment was not necessary after serological and microbiological exclusion of a florid systemic infection by antiseptic wound care with OCT/PE in conjunction with negative pressure wound therapy (NPWT) [65, 66]. With the introduction of a new treatment algorithm for chronic lower leg and foot ulcers in a surgical

outpatient clinic, OCT-based antiseptics were implemented instead of obsolete agents such as CHD, ethacridine, H₂O₂, silver sulfadiazine, or local antibiotics, with an almost 3-fold reduction in the total cost [67]. OCT was also effective in patients with inflammatory acne vulgaris [68].

Caveats

During the past few years, several misapplications of OCT/PE have been recorded. In these cases, the compound was applied in puncture wounds, bite wounds, or abscess cavities by syringe with pressure into the wound channel and deep tissue, instead of only superficial application. The subsequent edematous swellings with tissue damage required partial surgical revision [69]. Only superficial application by means of swabs or spray is recommended [70]. Any unwanted tissue reactions are improbable in this case, because no local pressure necrosis was observed upon flushing locally limited skin soft-tissue infections in the hand area ($n = 10$) with applied drainage [71]. Since OCT is practically not reabsorbed, any insertion into the skin or insertion canals is to be avoided. According to the manufacturer, the use of OCT/PE for wound treatment without medical supervision should not be extended for more than 2 weeks, as the only data available are from a continuous application period of up to approximately 14 days.

Contraindications

Peritoneal lavage, retroperitoneal and intravenous application, allergy, application to hyaline cartilage, and CNS structures are contraindications. Interaction with CNS structures is recorded for CHD, and is considered valid for OCT as well until further data are available [59].

Polihexanide

In 1979, Good [72] combined PHMB, which until then had only been used as disinfectant, with polyethylene glycol 4000 to achieve improved wetting for use on wounds [72, 73]. In the 1980s, PHMB was introduced by Willenegger in Switzerland [74]. PHMB can be seen as a virtually detoxified CHD, as the molecular structure of PHMB monomers closely resembles the structure of CHD molecules, except for the terminal NH-group of CHD consisting of 4-chloroaniline, which is a potential human carcinogen [75]. This similarity explains both the comparable antiseptic efficacy and the worse tolerability of CHD compared to PHMB, due to the release of 4-chloroaniline in vivo [76]. Depending on the manufacturer, wound irrigation solutions release 0.02, 0.04, or 0.1%

PHMB, wound gel 0.1%, and wound dressings 0.1%. Reduction by $\geq 3 \log_{10}$ of typical wound contamination on test specimens was achieved by wound gel with a concentration of 0.1% in 30 min, 0.04% in 3 h, and 0.02% in 10 h. *Enterococcus faecium* was not sufficiently eliminated in 24 h [39]. As different concentrations of PHMB solutions were not examined on test specimens, it is not possible to deduce the optimal concentration for wound treatment. A single irrigation of contaminated traumatic wounds for 3 min was shown to be effective in a clinical trial on the prevention of SSI [21], and treatment duration should not fall below this as long as there are no other results. Using wound gel, exposure for at least 3 h is needed [39].

Results from in vitro and Animal Tests

The efficacy of PHMB does not substantially differ from that of OCT. PHMB is equally effective against methicillin-sensitive *S. aureus* and MRSA [77]. Higher pH levels, which typically develop in wounds (6.5–8.5) [78], decrease the efficacy of PVP-I but significantly improve that of PHMB. This suggests that PHMB might be advantageous for the management of wound infections, as both *S. aureus* and *P. aeruginosa* exhibited increased susceptibility to the antiseptic with rising pH levels. The inhibitory activity of chlorhexidine and OCT was only marginally affected by the pH in vitro, although a statistically significant improvement was observed against *S. aureus* at pH 9 for OCT [79].

In combination with undecylenamidopropyl betaine (Betaine), the antimicrobial effect is enhanced because of altered physical properties [80, 81], while in vitro cytotoxicity is reduced [80] and cleaning performance is improved [82]; the latter one could not be confirmed in a newer study because of the interference of the surfactant with the protein measurement [322]. Intracellular elimination is remarkable, as shown for *E. coli* [83], MRSA [84], and *Acanthamoeba* species [85]. Thus, PHMB (0.02%) is the preferred agent for the treatment of *Acanthamoeba* keratitis [85]. Efficacy against *P. aeruginosa* can still be observed in the presence of 4% albumin [86], 4.5% blood + 4.5% albumin [87], and wound exudates, while the expression of elastase is inhibited at the same time [88]. In a wound model on pigs, MRSA was significantly reduced after 72 h by PHMB in a wound treatment matrix based on collagen, while silver dressings were ineffective [89]. PHMB was effective against biofilm in vitro [90] and in animal models [91]. Loaded onto nanocellulose, PHMB was antimicrobially more effective than PVP-I [92]. No antagonism could

be shown against oxacillin, penicillin G, ampicillin, ceftazolin, cefuroxime, imipenem, gentamicin, erythromycin, doxycycline, levofloxacin, linezolid, or vancomycin [93]. Both in cell culture and animal wound models (rat, pig), wound healing was improved [31, 94–96]. Results of in vitro and animal tests (rat) are promising for the combination of PHMB and sericine, an ameliorator of wound healing, in a dressing [97]. Capillary density was significantly increased in the cremaster muscle (rat) by exposure to PHMB and OCT, while the diameter of arterioles was significantly increased only by PHMB [98]. The irritation potency of 0.02% PHMB is lower than that of antibiotic eye drops [99].

In 2011, the Committee for Risk Assessment of the European Chemicals Agency (ECHA) raised the suspicion that PHMB was a category-2 carcinogen (Carc. 2). Consequently, all products containing PHMB in a concentration of at least 1% had to be labeled accordingly from January 1, 2015. Compositions containing 0.1% required an annotation on the safety data sheet. This classification by the ECHA as category 2 “suspected of causing cancer” lacks scientific proof. The 2 studies used for the evaluation were feeding studies using extremely high PHMB concentrations far in excess of the no-observed-(adverse-)effect level. Only in the highest tested concentration of 4,000 ppm did the frequency of cases with hemangiosarcoma significantly increase, but at $\leq 1,200$ ppm this was not the case. Neither genotoxicity nor epigenetic changes [100] could be shown; therefore, it is very likely that hemangiosarcoma was triggered by enforced proliferation of the endothelium, as was proven for PHMB in wound healing. For risk assessment, it is critical that there be no systemic absorption up to the detection threshold of 10 μg for PHMB, so a health hazard can be excluded for antiseptic use according to regulations [detailed statement with references in 101, 102].

It is important to note that, in this context, the ECHA specifically excluded PHMB from the labeling requirements when used invasively or on the skin surface for wound irrigation or with dressings. The reason for this exemption is the regulatory classification of hazardous substances and their preparation to ensure occupational and environmental safety. Particularly exposure to larger amounts, which is possible during the production of these substances, has to be considered. Personnel should be appropriately protected against critical exposure.

Undesirable Effects

Two cases of a possible anaphylactic reaction triggered by PHMB could not be verified in the skin-prick test [103]. One patient with a grade III anaphylactic reaction had IgE against both PHMB and CHD. Due to the similar structures, it is discussed that sensitization was caused by a prior treatment with CHD, so a known allergy against CHD might be linked to a risk for PHMB anaphylaxis [104]. In the second case, only IgE against PHMB was proven [105]. A further suspected case of anaphylaxis was reported after wound application [106]. Contact allergies are rare, with a frequency of $\leq 0.08\%$ in regard to the frequent use of PHMB, especially as a preservative [107]. This suggests that antiseptic substances should be limited to medical applications.

Clinical Trials

PHMB is available as a solution, hydrogel, and in wound dressings [108]. It is well tolerated [109], antiseptically effective against MRSA and VRE (vancomycin-resistant *Enterococcus*) [110–112], can be used for wound irrigation, is suitable as an antiseptic for critically colonized and infected chronic wounds, including burns [37, 94, 113–124], and, in combination with NPWT, can be used for instillation (NPWTi). It is superior to Ag⁺ and PVP-I regarding wound healing [123] (Table 7). Upon application of wound dressings impregnated with 0.2% PHMB, epidermally applied *Staphylococcus epidermidis* were completely eliminated in 24 h [125]. The same was shown for *P. aeruginosa* in an animal model [126]. Application for pre- and postoperative wound treatment significantly reduced the rate of SSI (Table 7). Cytotoxically, wound dressings do not differ from PHMB-free dressings [127]. After a 4-week unsuccessful treatment of a diabetic foot ulcer with PHMB/betaine gel, the healing process commenced after a 4-week treatment with OCT gel [128]. In cases with human papillomavirus infection, the viral elimination was significantly improved by local treatment with PHMB, examined after 3 and 6 months, which could open a new area of application [129].

Caveats

Due to the relatively strong binding onto tissue structures, the same restrictions as those for OCT should apply, although no clinical reports are available yet. This is supported by the appearance of grayish, inert tissue after retroperitoneal, mediastinal, and partially inguinal application for more than 5–10 days. This tissue had to be removed in order to permit the formation of granulation

Table 7. Summary of clinical study findings for PHMB

Type of wound	Comparison	Result	Study design	Sample size, <i>n</i>	Year
Traumatic soft tissue injuries	0.04% PHMB, 1% PVP-I, 4% WPO, Ringer solution	SSI rate: 1.9/4.8/11.7/5.9; PHMB was more effective in preventing infection in deep incisional wounds (A1 and A2 SSI), in contusion wounds only in A2 SSI	Longitudinal cohort study	3,264/ 2,552/ 643/645	2017 [21]
Pressure and VLU	PHMB/betaine solution vs. NaCl solution	Significant improvement of inflammation and wound healing, no difference in pain scores	Single-blinded RCT	143/146	2016 [287]
Wounds in elderly patients	PHMB/betaine solution	Significant decolonization with 32% success ($p < 0.05$)	Prospective controlled nonrandomized open-label study	200/99	2016 [112]
Nonhealing wounds after cardiothoracic surgery	PHMB 0.5% vs. moist gauze soaked with Ringer solution	Superficial infection 38 vs. 47%, (ns), deep infection 44 vs. 40% (ns), wound healing after 15 ± 5 vs. 16 ± 3 days (ns); wound healing in 67 vs. 44% (ns); PHMB: patients without complete wound healing showed better epithelialization, after 12 h CRP was significantly lower than controls	Prospective open randomized cohort study	15/16	2015 [288]
Chronic wounds	PHMB gel vs. betaine gel	Significant reduction in wound size, pain, fibrin slough, and necrosis; reduction of exudate	Multicenter observational study	120	2014 [289]
Grade II burns	PHMB gel vs. betaine gel	Less pain medication, good progress in wound healing with formation of granulation tissue and epithelialization; reduction of erythema after 2 days; no infection during mean treatment of 11.2 days	Observational study	20	2014 [290]
Postsurgical subcutaneous abdominal infections	NPWTi with 0.04% PHMB-soaked gauze vs. NPWT	Reduced duration of treatment	Prospective case-control study	16	2014 [291]
Wounds after cardiothoracic surgery	W vs. W+PHBM	PHMB: significant decrease of SSI	Cohort study	692/707	2013 [292]
Critically colonized and infected chronic wounds	PHMB vs. Ag-W	PHMB: significantly faster pain reduction and elimination of microorganisms	RCT	21/18	2012 [293]
Entry point of external fixator	W vs. W+PHBM	PHMB: significant decrease of SSI	RCT	18/22	2012 [294]
Lower-limb and foot ulcers	W vs. W+PHBM	PHMB: significantly faster pain reduction and elimination of microorganisms, tendentially faster wound healing	Double-blinded RCT	22/23	2011 [295]
Burns	W vs. W+PHBM	PHMB: significant pain reduction and fewer dressing changes	RCT	30/30	2011 [296]

Table 7 (continued)

Type of wound	Comparison	Result	Study design	Sample size, <i>n</i>	Year
Split-skin harvest sites	CHD W vs. PHMB W	PHMB: significantly faster reepithelialization and lower pain score	RCT	21/21	2011 [297]
Infected orthopedic implants	NPWTi with PHMB 0.04%	86% of patients with acute and 80% of patients with late-onset infections kept their implant during a follow-up time of 4–6 months	Prospective multicenter observational study	32	2011 [298]
VLU	NaCl vs. PHMB solution	PHMB: significantly faster bacterial elimination	Prospective cohort study	20/20	2010 [299]
Postsurgical wounds	W vs. W+PHMB 0.2% (first and possibly second dressing after surgical procedure)	PHMB: significant reduction in SSI, particularly of MRSA infection	Historic comparison	9,372/10,202	2008 [300]
Chronic wounds	NaCl vs. 0.1% PHMB gel	PHMB: after 2 weeks significantly faster bacterial elimination, faster wound healing, less pain, less exudate, improved granulation	Randomized nonblinded cohort study	64/78	2008 [301]
Burns	PVP-I, 1% silver nitrate, 0.04% PHMB	PHMB: improved epithelialization and elimination of malodor; deep necrosis and slough observed in PVP-I and silver nitrate study section	Parallel intervention on contralateral symmetric wounds	4	2007 [113]
Acute contaminated wounds	PHMB-wetted gauze (0.04%) vs. Ringer solution	Significant faster bacterial elimination, reduction of inflammation	Double-blinded RCT	28/22	2006 [302]
Infected wounds	W vs. W+PHBM	PHMB: improved control of wound colonization	RCT	21/21	2004 [303]

NPWTi, negative pressure wound therapy with instillation of antiseptics; W, wound dressing.

tissue, even after infection control independent of PHMB use as a single substance or in combination with betaine (Fig. 1a, b).

Contraindications

The 2 most important contraindications are possible allergy and application during the first 4 months of pregnancy. In later stages its use should follow strict observance of a benefit-risk assessment.

Sodium Hypochlorite/Hypochlorous Acid

The successful stabilization of the combination NaOCl/HOCl provided an ecologically relevant new development, because aqueous sodium chloride solution is

electrochemically converted for its production. The activated solution is also called electrolyzed water [130]. The currently used concentration amounts are 0.004% each for NaOCl and HOCl, and <0.06% for NaOCl as a mono-substance. In contrast to surface-active substances, the ion OCl^- is formed during phagocytosis through enzyme mediation by myeloperoxidase, eosinophilic peroxidase, and superoxide dismutase, and presents a physiological bactericidal mechanism [131].

Results from in vitro and Animal Tests

In tests without wound-related contamination, e.g., proteins or blood, and more specifically only in aqueous solution, NaOCl/HOCl and NaOCl are highly effective against vegetative bacteria, bacterial spores, aspergilli, oocysts of cryptosporidia, and coated viruses (HIV, HBV).

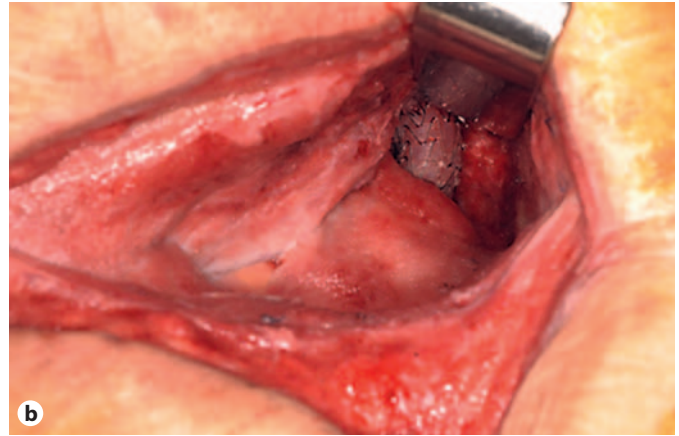
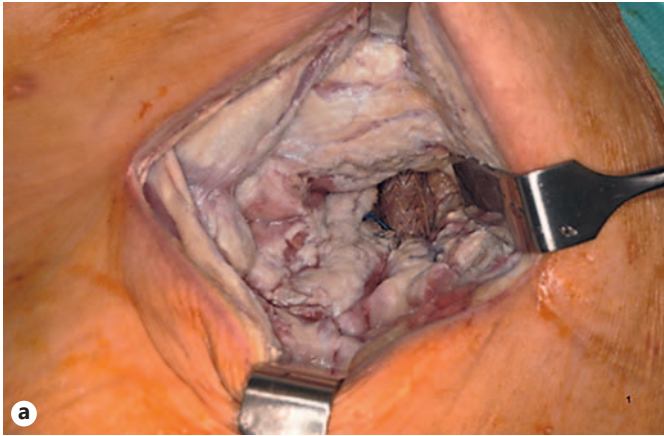


Fig. 1. Retroperitoneal instillation with PHMB on an aortic endoprosthesis infection. **a** Situs after 14 days and multiple excisions of the yellowish-brownish slough within 10 days. **b** Situs after a 16-day instillation with physiological NaCl solution. Source: D. Mayer.

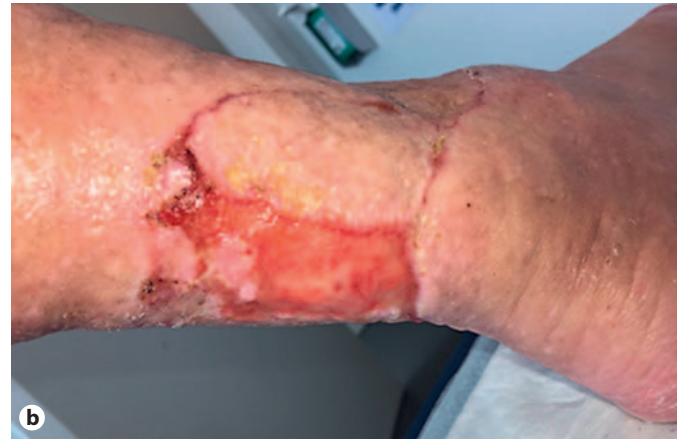
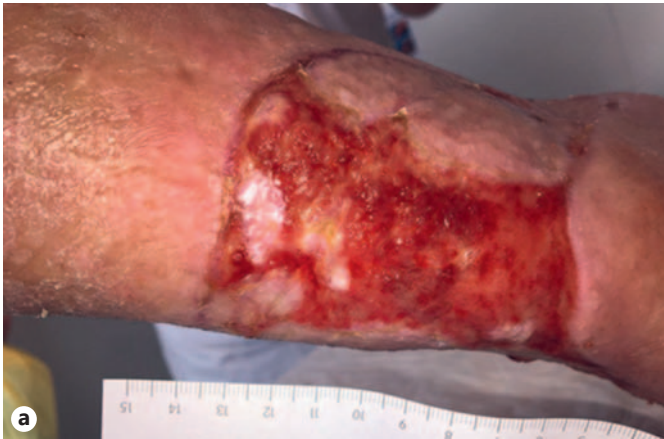
Fig. 2. A 90-year-old patient after excision of an ulcer hypertonicum Martorell and coverage with a split-skin mesh. **a** In due course, the formation of slightly bleeding, instable hypergranulations, which are possibly a sign of incipient infection. **b** After 2.5 weeks of daily dressing change and coverage with a Betadine gauze, the hypergranulations regressed and stable granulation tissue developed with a marked swelling of the wound vicinity. Source: D. Mayer.

The combination of PHMB/betaine was slightly less effective than NaOCl/HOCl against biofilm [132]. The speed of effect was superior to PVP-I, OCT, and PHMB [130, 133–137]. It can be assumed that the efficacy is reduced by protein or blood contamination, which can be reversed by repetitive extensive wound irrigation. The survival rate of rats with experimental peritonitis was significantly increased compared to a treatment with NaCl without undesirable effects [138]. By stabilization of the cell membrane, the release of cytokines from mast cells is

inhibited without intracellular impairment, possibly contributing to an anti-inflammatory effect [29]. NaOCl/HOCl was not or barely irritating on chick chorioallantoic membranes [323]. Furthermore, no evidence for cytotoxicity could be found in a 3D model of the skin [132]. There is no evidence for toxic risks [139]. The feeding of laboratory animals with 5 ppm is a safe alternative instead of sterile water [140]. There is no evidence that NaOCl poses a carcinogenic hazard [141, 142].

Undesirable Effects

Rinsing of the mediastinum in heart surgery with NaOCl/HOCl prior to wound closure was significantly associated with perioperative alterations of the ECG, including ST elevation, but without hemodynamic disturbances [143].

Clinical Trials

Case studies on NaOCl/HOCl report decolonization of MRSA infections on skin and the base of the skull [144, 145], decolonization of MRSA, *P. aeruginosa*, and *E. coli* in chronic diabetic ulcers [146], and successful adjuvant application in the treatment of necrotizing soft tissue infection [147], osteitis [145], and osteomyelitis [148]. In cases of peritonitis, partially with peritoneal abscess ($n = 7$), no bacterial growth was detectable 3–7 days after irrigating twice daily for 9–12 days [149]. Postoperative complications including SSI were significantly reduced in patients with peritonitis without symptoms of intolerance [150]. The irrigation of infected chronic wounds was well tolerated [151], also in combination with NPWT [152]. The combination NaOCl/HOCl with a hydrophobically coated wound dressing, to which microorganisms adhere and bind irreversibly, appears promising and to lack the subsequent physiological immune response impairment that is triggered by OCl^- (Table 8).

Iodophore

The introduction of iodophores, complexes of iodine and macromolecules, in 1956 sparked a renaissance of antiseptics. However, demands for stricter indications were already made in 1984, with a call for each specialty to more rigorously watch for undesired effects to prefer an antiseptic agent with similar antimicrobial spectrum but fewer undesirable effects [153]. Especially the risk of thyroid gland dysfunction, but also the relatively high potency for allergic sensitization, has led to a restricted application of PVP-I during recent years.

The macromolecular carrier system of PVP and the release of iodine after degradation by reacting agents result in lower iodine absorption, cytotoxicity, and sensitization, and thus in better tolerability than aqueous or alcoholic iodine solutions. In aqueous solutions, only a thousandth of the total iodine is free and microbicidally active. The development of liposomal PVP-I compositions (PVP-I-L) on the basis of hydrogel improved the wound tolerability [30, 154].

In contrast to PVP-I, cadexomer-iodine (C-I) uses a hydrophilic, modified starch polymer to embed iodide ions. The advantages of C-I are similar to those of PVP-I; however, PVP-I and C-I show different properties regarding the reactivity of iodine and water absorption [155]. C-I did not become as widespread in German-speaking regions as PVP-I did.

In vitro and Animal Experiments

The microbicidal effect is observed for all vegetative pathogens, including mycobacteria, yeasts, and dermatophytes, enveloped and nonenveloped viruses (including rabies especially in combination with alcohols), as well as protozoa, and, with a longer exposure time (2–24 h), also bacterial spores [156]. Depending on the test model, the efficacy of PVP-I in vitro can be higher than, comparable to, or less than OCT and PHMB; 10% sheep blood does not affect the efficacy. In 10% serum albumin as well as 4.5% sheep blood + 4.5% serum albumin + 1% mucin, the exposure time doubles, similar to OCT [38, 39]. In contrast to OCT and PHMB, PVP-I has no remanent effect. Extended antiseptic effects, shown in vitro, are not due to a true remanent effect in PVP-I, in contrast to OCT or CHD, but are an artifact of the modified release kinetics of the iodine from the PVP molecule, which follows the second order of kinetics.

In vitro, PVP-I inhibits the formation and release of inflammatory mediators due to the reduced expression of bacterial exotoxins, the inhibition of excessive mediator molecule release, and the activity of human immune effector cells, as well as the inactivation of tissue-destroying enzymes [157, 158]. Through chemical reactions with the physiological H_2O_2 peroxidase systems, oxidation products with a higher efficacy than that of molecular iodine can be formed in wounds [156]. C-I ex vivo and in animal models has a strong effect against biofilm-forming *S. aureus* and *P. aeruginosa* [159]. The contrasting effects against biofilms are attributed to the different availability of active iodine in the various forms administered [160]. In animal experiments, the healing of skin wounds was significantly delayed by 2% PVP-I [161]. For PVP-I-L, proliferation and improvement of microcirculation have been demonstrated in in vitro and animal experiments [30, 162, 163]. In animal models, the application of C-I promotes epithelial cell regeneration and thus wound healing [164, 165]. In PAOD (peripheral arterial occlusive disease)-associated ulcers, C-I was tolerated without irritation [166]. In accordance with this, in histological tests, no tissue damage was observed in the treatment of chronic exudative wounds [167]. There is no evidence of neurotoxicity, mutagenicity, carcinogenicity

Table 8. Summary of clinical study findings for the combination NaOCl/HOCl

Type of wound	Comparison	Result	Study design	Sample size, Year <i>n</i>
Explorative laparotomy/ peritonitis	NaOCl/HOCl vs. NaCl	OCl: significant reduction of fever and prevention of SSI	RCT	50/50 2013 [150]
Diabetic foot ulcers, VLU, burns	NaOCl/HOCl vs. PVP-I	OCl: faster granulation and epithelialization, faster reduction of wound size, reduction of surrounding edema and erythema, better cosmetic results in burn wounds; PVP-I: minute skin irritation and pain in burns	RCT	100/100 2011 [304]
Chronic wounds, SSI	NaOCl/HOCl vs. PVP-I	OCl: significant wound size reduction, fewer persisting infections due to <i>P. aeruginosa</i> , <i>S. aureus</i> , and <i>Klebsiella</i> spp.	RCT	50/50 2011 [305]
Diabetic foot ulcers	NaOCl/HOCl vs. PVP-I	OCl: significantly better wound healing, control of infection, significantly more interventions in the PVP-I study section	RCT	20/20 2010 [306]
Chronic wounds	NaOCl/HOCl vs. PVP-I	OCl: significant wound size reduction, better control of microbial colonization; was well tolerated	RCT	15/15 2009 [307]
Diabetic wounds	NaOCl/HOCl vs. NaCl (soaked gauze)	OCl: significantly reduced hospitalization and wound size, improvement in wound score	Blinded RCT	50/50 2007 [278]
Diabetic foot ulcers	NaOCl/HOCl vs. PVP-I	OCl: significant reduction of malodor, significant reduction of soft tissue infection, improved granulation, lower occurrence of erythema	Blinded RCT	21/16 2007 [308]
Diabetic foot ulcers	NaOCl/HOCl vs. PVP-I	OCl: reduced treatment time	RCT	110/108 2005 [309]
Burns	NaOCl/HOCl vs. Ag	OCl: 11% reduction in use of antibiotics, 50% reduction in hospitalization	Retrospective cohort study	64/64 2005 [310]
SSIs	NaOCl/HOCl vs. PVP-I	OCl: significantly reduced hospitalization and reduction of pain	Retrospective cohort study	46/42 2001 [311]

ty, or teratogenicity [156, 168]. In the cell culture (fibroblasts), 0.45% C-I was found to be noncytotoxic [167].

Side Effects

Iodophores display a high sensitization potential [169]. In adults with no known thyroid disease, and in contrast to premature infants and newborns as well as small children, irreversible damage to the thyroid gland is not to be expected after a single antiseptic application of PVP-I. However, even in patients who do not have a thyroid condition, PVP-I should not be used for more than 7 days due to a risk of thyroid dysfunction [156]. Rare extrathyroidal side effects have been described, such as iodine acne, runny nose, conjunctivitis, gastroenteritis, bronchitis, parotid

swelling, and renal impairment [170]. In the case of C-I application, temporary pain may also occur [171].

Clinical Studies

Clinically, wound healing was generally not impaired by PVP-I. However, in some cases the control group had a better outcome [172], probably promoted by C-I [165], although PVP-I showed worse results than OCT and PHMB in terms of biocompatibility [173]. On the one hand, PVP-I has been shown to be less comfortable than medical honey and less effective in reducing the wound size than silver dressings [174], but on the other hand, it was superior to silver and C-I dressings regarding the amount of pain during medical dressing changes [175].

In a prospective randomized controlled trial (RCT), PVP-I-L was significantly more effective and tolerable than a CHD-impregnated layer on a mesh graft [30]. Overall, iodophores offer no significant advantages over PHMB, active ingredients and wound dressings containing silver, medical honey, and nonantiseptic treatments. Exploitation of the antiseptic and cytotoxic properties of iodine in the treatment of pathological granulation tissue or hypergranulation tissue is of particular interest in wound healing. This is due to the mode of action, i.e., the pathophysiological approach of preventing tissue destruction by combating the “low-grade” infection (Fig. 2a, b), unlike in conventional methods, such as silver nitrate etching or surgical resection. Within 2–3 weeks of treatment with iodine gauze, fragile, bleeding hypergranulation tissue transforms into stable, healthy, vital granulation tissue.

Caveats

Considering the broad availability of new antiseptics, the application of iodophores must be evaluated carefully [176]. If PVP-I is continuously used, thyroid function must be checked in patients with euthyroid goiter, or in patients with any known thyroid disease, during pregnancy and lactation, and before extensive use in premature and newborn infants, as well as in infants up to 6 months old. Because of its cytotoxicity, repeated use is not recommended in chronic wounds, especially on transplanted mesh grafts (this does not apply to PVP-I-L).

Contraindications

PVP-I allergy, hyperthyroid goiter, dermatitis herpetiformis Duhring, use before and after radioiodine treatments, as well as peritoneal lavage [156] contradict the use of C-I. Hashimoto’s thyroiditis, pregnancy, lactation, and an age below 12 years are additional contraindications for C-I [171].

Taurolidine

Taurolidine was introduced in 1981, and although initial results seemed promising, scientific studies still show unsatisfactory results.

In vitro and Animal Experiments

Due to the slow elimination of the formaldehyde molecule, the antiseptic efficacy of taurolidine only begins after 6–24 h *in vitro* [177]. Therefore, antiseptic efficacy can only be expected in long-term applications. Another mode of action is based on the antiendotoxin effect of the

cross-linking of muramyl peptides in the bacterial cell wall by transferring methylol groups from the taurolidine molecule. This is intended to reduce the release of inflammatory mediators. In peritonitis, the inflammatory-induced serum levels of TNF- α and interleukin-1 decreased, and the survival rate increased after the application of taurolidine [178, 179]. Furthermore, the activity of fibroblasts, the hydroxyproline tissue levels, and the mechanical stability in anastomoses increased [180]. In a monolayer cell culture of human amniotic cells, no cytotoxicity was detected even with complete replacement of the cell culture medium by taurolidine 2% [181]. On peritoneal explants, taurolidine Ringer 0.5% was completely tolerated (with a slight increase of growth promotion). Regarding the tolerability of peritoneal explants, taurolidine 2% was comparable to 0.04% PHMB [182]. Despite the good *in vitro* tolerability of taurolidine, epithelialization was significantly delayed in secondary wound healing in the animal model (rat) [183].

Clinical Studies

Despite the the expectations due to the mechanism of action and the proven partial reduction of the bacterial count in the peritoneum, the outcome did not verifiably improve after a prophylactic peritoneal lavage [184], nor did it improve the outcome when treating sepsis and various forms of peritonitis [185–188], compared to rinsing with physiological NaCl solution. After a first unsuccessful treatment of septic ulcers with 0.04% PHMB or 8-quinolinol, bacteria were eliminated after changing to taurolidine 2% (soaked dressings) after 2, 6, and 7 days. Although a patient showed a slower elimination of bacteria, his status continuously improved and the wound showed good epithelization after 28 days, such that the patient could be transferred to outpatient treatment [189]. Because of associated pain, taurolidine had to be combined with a local anesthetic. Due to limited data, currently taurolidine cannot be recommended for wound antiseptics.

Silver Ions

Silver-releasing compounds have been used since ancient times for wound treatment. However, silver in its elemental form has no antimicrobial effect. Antimicrobial activity develops only after the silver atoms lose an electron and become positively charged silver ions.

In vitro and Animal Experiments

Silver ions bind to peptide glycans of the bacterial cell membranes and thus lead to their destruction. Silver ions, which are transported into the cell, interfere with numerous cell functions by binding to proteins and interfering with energy generation, enzyme function, and cell replication. Thanks to these diverse points of attack, the development of resistances against silver ions has to date only been rarely described [190].

Clinical Studies

A great practical problem in the evaluation of wound therapeutics with silver is based on the extreme heterogeneity of the products. Thus, it is not surprising that 2 Cochrane meta-analyses [191, 192] have come to the following conclusions: silver can inhibit wound secretion and odor, and some studies showed a promotion of wound healing, but other studies showed a delay in wound healing. Currently, there are not enough studies with high-level evidence for a general recommendation of silver-containing wound dressings to improve wound healing or to treat or prevent wound infections. However, this also applies to most other antiseptic therapeutics used for wound treatment. A recent meta-analysis of clinical trials over the last 15 years shows that out of 39 clinical trials on the subject of silver in wound treatment, 31 were RCTs. In 28 of the 39 controlled studies, positive aspects were described for wounds, such as accelerated wound healing and bacterial reduction as well as positive aspects in quality of life or pain reduction. On the basis of an expert recommendation, the use of silver in the treatment of critically colonized or infected wounds, as well as in the case of a detected MDRO, was recommended for a maximum of 14 days. After this period, a critical reevaluation of the usefulness of silver-ion therapy should be performed. However, an extensive, long-term and prophylactic use was not recommended [190].

Inadvisable or Obsolete Agents

CHD has now generally been replaced by OCT, PHMB, and, in the case of acute bite wounds, PVP-I. The reasons for this are the risk of anaphylactic reactions [193], the progressive development of resistant microbes, and the increased cytotoxicity compared to OCT and PHMB. Topical silversulfadiazine has lost its significance based on recommendations to avoid the topical use of chemotherapeutics, its cytotoxicity, its risk of absorptive side effects, and the unwanted formation of

hardly soluble complexes between the cream and wound proteins making wound analysis (burn depth detection) virtually impossible in burn patients. Therefore, the indication for necessary surgical treatment in patients with deep second-degree burns may be overlooked or delayed due to the adherent scab [194]. Chinolinole [195] and nitrofurazone [196] do not meet the formal requirements of an effective antiseptic agent, nor are there convincing clinical data proving their efficacy. Moreover, both agents bear toxic risks, and the risk-benefit analysis speaks against their use. Dyes, organic mercury compounds, pure H₂O₂, as well as topical antibiotics, are considered obsolete [194].

Recommended Antiseptic Agents

Table 10 shows a comparison of indications for most antiseptics (no comparative studies exist between NaOCl/HOCl, OCT and PHMB) according to the literature.

OCT: The combination 0.1% OCT/PE solution is suitable for acute, contaminated, and traumatic wounds, including MRSA-colonized wounds, due to its deep action. For chronic wounds, preparations with 0.05% OCT are preferable. The latter are available as gels or rinses combined with surface-active ethylhexylglycerin.

PHMB: The following recommendations can be made according to a literature review: level A (= strong support that merits application): therapeutic option for acute traumatic wounds, chronic ulcers and second-degree burns due to its analgesic effect; level B (= moderate support that warrants consideration of application): (cost-)effective treatment of wound infections, promotion of wound healing, and treatment of moderately exuding recalcitrant wounds [197]. Therefore, PHMB may be considered the first-choice agent for infected chronic wounds and burn wounds (gel, dressing). Furthermore, PHMB efficiently decolonizes MRSA in chronic wounds. In surgery, PHMB reduced the rate of SSI after primary debridement, placing external fixator entry ports, and poststernotomy sutures after cardiac surgery. However, due to its retrospective cohort study design and small sample size (Table 7), more evidence is needed for the latter indications. Given its spectrum of activity, PHMB is considered active against Gram-negative MDROs. However, the results of broad-spectrum tests leave some doubt as to whether PHMB is an effective agent for the treatment of VRE [39].

Hypochlorite: NaOCl or NaOCl/HOCl are first-choice agents for single or repetitive intensive, antiseptic cleans-

ing of contaminated traumatic wounds and for the repetitive antiseptic cleansing of chronic wounds for the duration of the cleaning phase. Colonization with MRSA is effectively eradicated. OCl⁻ may even be used for antiseptics when structures of the CNS are exposed or, in the case of peritonitis, as an antiseptic agent for peritoneal lavage.

PVP-I: a recent systematic review [172] concludes that PVP-I should no longer be used in the treatment of chronic wounds. This, however, does not apply to liposomal PVP-I (PVP-I-L), as epithelialization is promoted [198]. Detailed studies investigating improved PVP-I formulations are lacking; thus, the effectiveness of PVP-I-L on healing of chronic wounds cannot definitely be assessed at this stage. There is a lack of evidence for the use of PVP-I as a cleaning solution for the prevention of SSI in acute traumatic soft tissue injuries [21]. However, in combination with alcohol, e.g., ethanol, PVP-I is still the first-choice agent for infection prevention in acute stab, cut, bite, or gunshot wounds due to its ability to penetrate deeply into the wounds [199]. Its excellent tissue penetration makes PVP-I (only on an aqueous basis!) a possible candidate for use in the heavily destroyed tissue of traumatic wounds, such as those resulting from car-crashes or explosions.

Basic Rules of Antiseptic Treatment in Wound Management, Based on Wound Type

Before the application of an antiseptic agent, the following rules must be considered [200]:

- Determine the correct diagnosis (i.e., etiology) of any chronic, nonhealing wound! The best antiseptic is ineffective if the initial cause for infection is not treated.
- Cleansing and debridement of (chronic) wounds are crucial! Otherwise, antiseptics are ineffective.
- Manage any wound according to its healing phase, especially regarding wound dressings [201]. Every dressing change should be done meticulously following basic antiseptic rules [202].

As a matter of principle, the therapeutic regimen should be reviewed after 2 weeks of unsuccessful application of an antiseptic, including further diagnostics and, for example, analyzing local blood flow in order to avoid continuing an unsuccessful regimen ad infinitum. Although rinses usually do not have a predetermined limit for the duration of their application due to their status as an MD, this practice should also be implemented when treatment with these solutions proves unsuccessful.

Bite and Stab Injuries [199, 203]

Acute open wounds should be thoroughly debrided and rinsed with PVP-I/alcohol. In case of contraindications, OCT/PE is a promising option. In the first 4 h, no antibiotic prophylaxis is needed and open wound treatment is continued.

In the case of virtually “closed” acute injuries (e.g., cat bites), deep surgical debridement must be carried out and the wound should be covered by a PVP-I/alcohol- or OCT/PE-soaked dressing. Alternatively, if a distal phalanx is involved, for example, the finger could be immersed in a PVP-I/alcohol or OCT/PE bath. PHMB does not exhibit a deep effect without adjuncts enhancing deep penetration. The penetration depth for hypochlorites is unknown.

For injuries or wounds older than 4 h, besides following the above rules, antibiotics should be administered orally or intravenously according to current guidelines (e.g., empirical evidence supports starting with ampicillin or amoxicillin; in most cases, a single injection will suffice).

For injuries or wounds older than 24 h, the same rules apply. However, if the wound seems clinically inflamed or infected, excision should be considered and antibiotics are usually administered for a longer period. Surface-active antiseptics should not be applied under pressure and continuous drainage should be guaranteed.

Burns

For possibly lethal cases, the administration of broad-spectrum antibiotics is crucial. After necrosectomy and escharotomy, the wounds and, later, freshly applied skin grafts are continuously moistened with antiseptics. Adjuvant systemic treatment consists of specific, adequate nutritional support and the substitution of factors that promote wound healing [204]. However, smaller burns can be managed and healed conservatively using antiseptic dressings [205]. Antiseptics of choice are gels on the basis of PHMB. The effectiveness of devices and dressings containing silver ions remains unclear [191, 192, 194, 206, 207, 272].

Antiseptic Irrigation/Rinsing

It has been shown that a single irrigation/rinse with an antiseptic agent reduces the SSI rate after surgical management of acute, contaminated wounds [21]. The same holds true for intraoperative irrigation/rinsing before surgical wound closure [208].

Decolonization of MRSA-Colonized Wounds

The main indication for decolonization is to prevent the spread of nosocomial infections. Decolonization of MRSA in the nasal vestibule is usually successful after 7 days [209]. Burn wounds are decolonized after 5 days [210], whereas chronic wounds need to be treated with mupirocin for 14 days [211, 212].

Treatment of Locally Infected or Critically Colonized Wounds

For these types of wounds, routine treatment with an antiseptic agent is required (examples are given in Tables 6–9).

Future Perspectives

NPWT with Instillation of Antiseptic Agents

NPWT exerts no direct antimicrobial effect. Therefore, instillation of an antiseptic agent in combination with NPWT, called NPWTi, is being increasingly promoted as a promising combination in wounds with a heavy bioburden [213–218].

NPWT may be considered a special form of semioclusive “moist” wound dressing with virtually unlimited drainage capacity. Through direct contact and interaction of the foam with the wound, the granulation process is promoted [216] and tissue perfusion improved [219]. In an animal model, where excision wounds on the back of pigs were infected with *P. aeruginosa*, instillation of physiological NaCl combined with NPWT (NPWTi) was clearly more effective in reducing the bioburden than NPWT alone; instillation with PHMB significantly enhanced this effect [220]. Positive results of smaller studies using PHMB, mostly without long-term follow-up [221], have recently only been partially confirmed by larger, systematic studies (Table 10). Therefore, further RCTs are needed to clarify the role of PHMB in NPWTi. Further experiments in infected pig wounds showed a significant reduction of bioburden after 48 h using a combination of NPWT and a dressing containing silver ions, as well as with cyclic instillation of OCT (for 3 min every 4 h) and NPWTi compared to NPWT alone [222]. In an exemplary case of a patient with a high-risk of skin graft failure due to comorbidities, the application of NPWTi with OCT led to uneventful healing. A second patient developed skin graft necrosis after the use of PVP-I; regrafting and a change to NPWTi with OCT was followed by uncomplicated healing [223]. In both studies, a solution with 0.05% OCT without the addition of PE was used. Grade-4 gluteal pressure ulcers 4

($n = 3$) treated by NPWTi with OCT healed completely within 4 weeks [224]. Representative studies (e.g., RCTs, larger prospective cohort studies) using NPWTi in combination with OCT are still lacking. The single study of NPWTi with NaOCl has merely indicative character (Table 11). Due to aseptic necrosis after the application of OCT into tissue, Willy et al. [225] recommend a limited use of NPWT with OCT in case of deeper injuries.

Acetic Acid

Generally speaking, an acidic wound environment supports control of infection, toxicity of bacterial metabolites, protease activity inhibition, release of oxygen, and epithelialization as well as angiogenesis [226].

In vitro and Animal Study Results

AA is, just like NaOCl/HOCl, a physiologically active substance. It was already noticed in 1916 that colonization with *P. aeruginosa* was only rarely observed in an acidic wound environment [227]. When comparing different acids, AA showed a superior effect [227, 228]; at pH 3, the antimicrobial effect was 10–100 times stronger compared to other acids. It is assumed that undissociated AA is able to penetrate the cell better due to improved lipid solubility. The MIC (agar dilution test, 72 h) was observed to be 9% for *S. aureus*, 8–10% for MRSA, 4% for *E. coli*, 3% for *Salmonella typhi*, and 2% for *P. aeruginosa* [229, 230]. In the dilution test (18 h) MIC varied between 0.16 and 0.31%. Biofilms were eliminated by 0.31% AA in 3 h [231]. The following reduction rates were obtained in suspension tests with concentrations that were nontoxic for fibroblasts after 15 min: 0.005% NaOCl >8 log versus *S. aureus*, *P. aeruginosa*, *E. coli*, *Enterococcus* spp., and *Bacteroides fragilis*. 0.0025% AA was only effective against *S. aureus* with <1 log₁₀ and *P. aeruginosa* with 3 log₁₀, 0.001% PVP-I was effective only against *S. aureus* with 3 log₁₀ and *P. aeruginosa* with <1 log₁₀, while 0.003% H₂O₂ was ineffective against all test organisms [232]. In the quantitative suspension test, 1% AA eliminated *Proteus vulgaris*, *P. aeruginosa*, *Acinetobacter baumannii*, and β-hemolytic streptococci within 5 min, and *S. aureus* and *S. epidermidis* within 10 min. 0.04% PHMB, OCT/PE, and PVP-I 11% also only needed 5 min to accomplish this, but 10 min were necessary against *P. vulgaris* [233]. In cell culture with fibroblasts, 1% PVP-I (IC₁₀₀), 3% H₂O₂ (IC₁₀₀), 0.5% NaOCl (IC₁₀₀), and 0.25% AA (IC₂₅) proved to be cytotoxic [47]. In an animal model with aseptic wounds down to the fascia, epithelialization was only delayed significantly up to the 8th day with the tested concentrations, and H₂O₂ proved completely ineffec-

Table 9. Summary of clinical study findings for PVP-I or PVP-I-L and C-I

Type of wound	Comparison	Result	Study design	Sample size, Year <i>n</i>
VLU	C-I vs. standard treatment	Improved wound healing and lower costs with C-I	Review	4 RCTs 2016 [312]
Pressure ulcers (infected and noninfected)	PVP-I and C-I vs. nonantimicrobial treatment, lysozyme ointment, crystal violet, PHMB, silver sulfadiazine	Little evidence for improved wound healing in nonantimicrobial wound treatment interventions and noninfected wounds as compared to PVP-I	Cochrane review	12 RCTs 2016 [313]
VLU	PVP-I vs. hydrocolloid dressings	No observable differences	Cochrane review	6 RCTs 2014 [314]
Infected wounds	PVP-I vs. silver foam dressing	Significantly faster wound size reduction with silver	RCT	35/35 2014 [315]
Chronic wounds	PVP-I vs. medical honey	Improved results with medical honey in terms of wound size reduction, comfort, and pain during dressing change	RCT	20/22 2014 [174]
Chronic wounds	PVP-I vs. C-I vs. silver dressing	PVP-I: improved comfort and less pain during dressing change, lowest costs	Cohort study	20 2013 [175]
Chronic wounds, burns, pressure ulcer	29 RCTs comparing efficacy of PVP-I and C-I with hydrocolloids, silver, zinc, dextranomer, and NaCl solution	In some RCTs advantage of PVP-I over nonantiseptics and other antiseptics, particularly for burns; otherwise no benefit of one method against the other	Review	29 RCTs 2010 [172]

Table 10. Summary of clinical findings for wound antiseptics

Criteria	NaOCl/HOCl	OCT	PHMB	PVP-I
Antimicrobial efficacy	Yes	Yes	Yes	Yes
Improvement of wound healing	Yes	No inhibition	Yes	Partly inhibition
Peritoneal lavage in septic peritonitis	Possible	Contraindicated	Contraindicated	Contraindicated
Applicability of CNS tissue	Possible	Contraindicated	Contraindicated	Toxic [316]
Applicability on cartilage	Possible	Contraindicated	Only at <0.005%	Yes
Superior to Ag ⁺ PVP-I CHD	Tendentially better Significantly better No studies	Significantly better Tendentially better No studies	Significantly better Significantly better Significantly better	Tendentially better – No studies
Prevention of SSI	Possible	No studies	Effective	Tendentially better

Table 11. Summary of clinical study findings for NPWTi

Type of wound	Comparison	Result	Study design	Sample size, Year <i>n</i>
Infected wounds	NPWTi PHMB/PVP-I vs. NPWTi with NaCl solution	No difference in the number of surgical procedures, length of stay, wound healing rate; with NaCl: significant reduction in time to final surgical treatment	RCT	100/83 2015 [317]
Chronic wounds	NPWT vs. NPWTi PHMB + PVP-I	PHMB: significantly fewer dressing changes, shorter hospitalization, shorter surgical procedure times, faster wound closure, faster bacterial elimination	Retrospective case-control study	74/68 2014 [221]
Chronic wounds	PHMB-soaked gauze vs. NPWTi with PHMB-impregnated gauze	NPWTi: significantly better wound healing, shorter treatment time, elimination of bioburden	RCT	25/25 2013 [318]
Chronic wounds	NPWT vs. NPWTi with NaOCl 0.125%	Significant reduction of bacterial load per gram of tissue compared to NPWT alone	Prospective randomized sequential study	8/8 2012 [319]
Osteomyelitis	NPWTi with PHMB vs. historic control	PHMB: significantly faster reduction of infection, shorter hospitalization, fewer surgical interventions	Retrospective case-control study	30/94 2009 [320]

tive. The tear resistance of wounds was not impaired. *S. aureus* was eliminated by noncytotoxic concentrations of PVP-I (0.001%) and NaOCl (0.005%). For H₂O₂ and AA, however, the noncytotoxic concentrations proved ineffective [47]. A 0.15% AA solution stimulated wound healing [161]. For experimental wounds on rats and human split-skin removal sites, wound healing was generally accelerated with 0.25% AA, 11% PVP-I, and 3% H₂O₂, but after detachment of the scab, H₂O₂ caused blisters and ulcerations in contrast to AA and PVP-I [234].

Adverse Effects

On wounds, concentrations >2% caused pain [230] and >5% caused a burning sensation [235].

Clinical Studies

The concentrations effective for eliminating *P. aeruginosa* on small ulcerations and burns varied between 1 and 5%, and eradication occurred after 2–16 days [230, 235–239]. In burn patients, *P. aeruginosa* was eliminated after 2–17 days following a daily bath in 0.5% AA for 22–45 min [235]. After cleaning the wound with sterile NaCl solution, a compress drenched in 3% AA was changed daily and fixated via dressing. After 2–12 days, *P. aerugi-*

nosa was eliminated [236]. Using NPWTi with 1% AA (*n* = 3; instillation of 30 mL twice daily for 3 weeks, no control), the number of pathogens (MRSA, Gram-negative) was significantly reduced (*n* = 2) or eliminated; this was associated with improved healing and a shift from highly basic pH to a weak basic or neutral pH [240] (Table 12).

Contraindications

No contraindications are known.

Cold Atmospheric Plasma

Cold atmospheric plasma (CAP) is included in this analysis because it mainly consists of reactive-oxygen species (ROS) and nitrogen species (NO), and thus has highly antiseptic properties. It significantly surpasses PVP-I and PHMB in efficacy [241]. Against biofilms, it performs almost as well as PHMB and CHD [242]. On the skin, the efficacy is only slightly lower than that of OCT [243]. The plasma's idiosyncrasy is that biochemically active compounds are created instrumentally and display other qualities in addition to the antimicrobial effect. As with the introduction of portable laser technology and associated innovations, the development of mobile devices [244, 253] allows multiple local plasma applications. At

Table 12. Summary of clinical study findings for AA

Type of wound	Comparison	Result	Study design	Sample size, <i>n</i>	Year
Chronic wounds	1% AA vs. NaCl	AA: <i>P. aeruginosa</i> reduced significantly faster (day 7)	RCT	16/16	2016 [230]
VLU	0.25% AA vs. 0.25% chloramine	AA: 15-min wet-to-moist gauze application yielded a significant reduction of total colony count and <i>S. aureus</i> ; <i>P. aeruginosa</i> , <i>Proteus</i> spp., <i>S. epidermidis</i> , and <i>S. haemolyticus</i> group G with both test compounds was not reduced significantly	Quasi-experimental intervention study	45	1995 [321]
Burns or superficial wounds	5% AA vs. CHD or hypochlorite	AA: elimination of <i>P. aeruginosa</i> within 2–7 days in 8/10 patients and 1/10 after 4 days in the control group	RCT	10/0	1968 [238]

the moment, these are focused around the therapy of chronic wounds [245–249], tumors [250], and eliminating biofilm on implants [251–253].

The biochemically active compounds (electrons, ions, excited atoms and molecules such as ROS and NO, atoms or molecules with unpaired electrons, photons or electromagnetic fields) are created during plasma generation through interaction with molecules from the surrounding air and/or medium and body fluids or tissue.

The hypothesis [254, 255] for the analysis of plasma used in wound healing is founded on the following assumptions:

- Every healing process requires energy
- The center of chronic wounds is hypoxic and hypothermic, and an energy deficit will inhibit wound healing
- A higher tissue temperature (>38°C), elevated oxygen partial pressure (to provide aerobic energy), and increased blood circulation (for the transport of energy-rich substrates and metabolites) support wound healing
- Damaged cells in the wound area inhibit wound healing
- Critical colonization/biofilm formation or infection will block wound healing
- Endotoxin absorption or binding facilitate wound healing
- The existence of induced electrical flow and ion distribution based on electrical signals are important for cell migration and distribution at the edge of the wound

In vitro and Animal Experiment Findings

The microbicidal effect of CAP was observed in vitro [256–261] on skin and chronic wounds, and exceeds the effectiveness of CHD, PVP-I, and PHMB. In a 3D epidermis model, CAP displayed dose- and time-dependent compatibility [256]; *P. aeruginosa* was inactivated without destroying the structure of the epidermis. Cell proliferation is supported in cell culture [247]. For degree-IIa superficial dermal wounds and degree-III wounds with complete loss of skin on pigs, the wound healing duration did not differ from the control, and no increase in inflammation reactions or cell atypia was found. An increased IL-6 and IL-8 release was induced for keratinocytes and mononuclear cells. The support of circulation and angiogenesis was also observed [262]. On the chorioallantoic membrane, a heightened leukocyte-endothelium interaction with an increased fraction of rolling leukocytes and leukocytes solidly attached to the vascular endothelium (as a precursor to diapedesis into the surrounding tissue) was documented [247, 263]. This may signal an increase in inflammatory and immunological reaction due to the stimulus caused by CAP. No mutagenic potency was documented for the plasma source used in these experiments [264].

Clinical Results

The healing of chronic wounds for small animals (treatment duration 4–5 s/cm² of wound surface, twice a week) supports the hypothesis that the healing process starts with an intermediate acute inflammation. Because

Table 13. Orientating recommendation for the indication-based selection of wound antiseptics

Indication	Antiseptic compound	
	1st choice	2nd choice
Critically colonized wounds, wounds at risk of infection	PHMB	OCT, hypochlorite, silver
Burns	PHMB	OCT, hypochlorite
Bite, stab, and gunshot wounds	PVP-I	Hypochlorite
MDRO-colonized or infected wounds	OCT/PE	OCT, PHMB, silver
Prevention of SSI	PHMB	OCT/PE
Decontamination of acute and chronic wounds	Hypochlorite, PHMB	–
Peritoneal lavage	Hypochlorite	–
Risk of CNS tissue exposure	Hypochlorite	PVP-I
Wounds with lack of drainage	Hypochlorite	PHMB

CAP exhibits no remanent effect, OCT or PHMB was applied after each plasma treatment. The wound dressing was renewed daily and the wound was cleaned with the initially used antiseptic [265]. Regarding chronic ulcers in humans, however, no corresponding results were achieved, probably since CAP was not used in conjunction with remanently effective antiseptics [266]. There was no evidence of adverse reactions on human skin or chronic wounds. The penetration depth never exceeded 60 μm [247].

Caveats

Because of oxidative stress, the resulting formation of ROS and NO, and an increase in the inflammation cascade in burn wounds [267], application of CAP on burns should not be started before its safety has been confirmed in animal-based experimental studies.

Contraindications

No contraindications are known.

Conclusion and Practical Recommendations

Wound antiseptics are indicated for the treatment of critically colonized and infected chronic wounds, to prevent the development of infection in acute wounds with increased risk of infection, such as bites, stabs/punctures, or burns, for decolonization of wounds colonized with MDROs, and for the prevention of SSI. In case of a longer surgery duration (about ≥ 1 h), a single rinsing of the surgical area appears to be reasonable [225], since more than 50% of all surgical gloves are contaminated during this time [268].

Due to the paucity of clinical studies, the selection of wound antiseptics is based on both preclinical and clinical studies of nonuniform research quality and design. After assessing characteristics and the available research, it can be summarized that for critically colonized and infected chronic wounds as well as for burns, PHMB is the antiseptic of choice. For bites, stabs/punctures, and gunshot wounds, PVP-I is the first agent of choice, while PHMB and hypochlorite are superior to PVP-I for the treatment of contaminated acute and chronic wounds. For the decolonization of MDRO-colonized or infected wounds, the combination of OCT/PE is preferred. For peritoneal lavage or rinsing of other cavities with a lack of drainage potential as well as when the risk of CNS exposure exists, hypochlorite is the antiseptic of choice (Table 13).

Addendum

This consensus document was reviewed and formally approved by the respective boards of the following scientific societies: Antiseptics Working Group of the International Society of Chemotherapy for Infection and Cancer (ISC), German Society for Hospital Hygiene (Deutsche Gesellschaft für Krankenhaushygiene, DGKH), the Chronic Wound Initiative (Initiative Chronische Wunden e.V., ICW), Austrian Society for Infection Control (Österreichische Gesellschaft für Krankenhaushygiene, ÖGKH), Organization of all German-speaking Societies and Groups in Wound Management (Dachorganisation deutschsprachiger Vereine und Gruppen im Bereich Wundmanagement, Wund-D.A.CH).

Disclosure Statement

Axel Kramer discloses that in the past he has received research support, lecture fees, and travel-cost reimbursements from the following companies: Antiseptika chem.pharm. GmbH, B. Braun Melsungen AG, Bode/Paul Hartmann AG, Lohmann and Rauscher, Maquet GmbH, Schülke and Mayr GmbH, SERAG – WIESSNER GmbH and Co. KG, Oculus, Ethicon, and 3M Healthcare. However, the present publication is not connected with financial interests.

Joachim Dissemond discloses that in the past he has received research support, lecture fees, and travel-cost reimbursements from the following companies: Acclity, B. Braun, Coloplast, Con-vatec, Draco, Engelhard, Flen Pharma, Lohmann & Rauscher, Mölnlycke, Serag-Wiesner, and Urgo.

Ojan Assadian was a member of the Hutchinson Santé's medical advisory board and Mölnlycke Medical Advisory Board. He

declares having previously received travel and accommodation expenses, together with honoraria for teaching and participation in advisory/consultation groups from: Altrazael Europe Ltd., Antiseptica chem. GmbH, B. Braun Melsungen AG, Carefusion Ltd., Coloplast AG, Ethicon Ltd., K.C.I. Austria GmbH, Lohmann and Rauscher GmbH and Co. KG, Maquet GmbH, Mentor Deutschland GmbH, Mundipharma GmbH, Nawa Heilmittel GmbH, Quantum Management and Service GmbH, Schülke and Mayr GmbH, Smith and Nephew Ltd, and 3M Deutschland GmbH. Prof. Assadian declares that he has no stocks or other financial interests with any company or their products.

All other authors have no conflicts of interest to declare.

The present publication is not connected with financial interests. Where specific products are mentioned, the authors expressed personal opinion, based on scientific evidence and published data, with no company involvement.

References

- Poole K: Efflux pumps as antimicrobial resistance mechanisms. *Ann Med* 2007;39:162–176.
- Costa SS: Multidrug efflux pumps in *Staphylococcus aureus*: an update. *Open Microbiol J* 2013;7:59–71.
- Silver S: Bacterial silver resistance: molecular biology and uses and misuses of silver compounds. *FEMS Microbiol Rev* 2003;27:341–353.
- Hetem DJ, Bonten MJ: Clinical relevance of mupirocin resistance in *Staphylococcus aureus*. *J Hosp Infect* 2013;85:249–256.
- Then RL, Kohl I, Burdeska A: Frequency and transferability of trimethoprim and sulfonamide resistance in methicillin-resistant *Staphylococcus aureus* and *Staphylococcus epidermidis*. *J Chemother* 1992;4:67–71.
- Heuer H, Smalla K: Manure and sulfadiazine synergistically increased bacterial antibiotic resistance in soil over at least two months. *Environ Microbiol* 2007;9:657–666.
- Kopmann C, Jechalke S, Rosendahl I, et al: Abundance and transferability of antibiotic resistance as related to the fate of sulfadiazine in maize rhizosphere and bulk soil. *FEMS Microbiol Ecol* 2013;83:125–134.
- Mayer KH: Review of epidemic aminoglycoside resistance worldwide. *Am J Med* 1986;80:56–64.
- Cookson BD: The emergence of mupirocin resistance: a challenge to infection control and antibiotic prescribing practice. *J Antimicrob Chemother* 1998;41:11–18.
- Upton A, Lang S, Heffernan H: Mupirocin and *Staphylococcus aureus*: a recent paradigm of emerging antibiotic resistance. *J Antimicrob Chemother* 2003;51:613–617.
- Simor AE, Stuart TL, Louie L, et al: Mupirocin-resistant, methicillin-resistant *Staphylococcus aureus* strains in Canadian Hospitals. *Antimicrob Agents Chemother* 2007;51:3880–3886.
- Tam VH, Kabbara S, Vo G, Schilling AN, Coyle EA: Comparative pharmacodynamics of gentamicin against *Staphylococcus aureus* and *Pseudomonas aeruginosa*. *Antimicrob Agents Chemother* 2006;50:2626–2631.
- Briedis DJ, Robson HG: Comparative activity of netilmicin, gentamicin, amikacin, and tobramycin against *Pseudomonas aeruginosa* and *Enterobacteriaceae*. *Antimicrob Agents Chemother* 1976;10:592–597.
- Boyd LB, Maynard MJ, Morgan-Linnell SK, et al: Relationships among ciprofloxacin, gatifloxacin, levofloxacin, and norfloxacin MICs for fluoroquinolone-resistant *Escherichia coli* clinical isolates. *Antimicrob Agents Chemother* 2009;53:229–234.
- Deutsche Gesellschaft für Wundheilung und Wundbehandlung: Lokaltherapie chronischer Wunden bei Patienten mit den Risiken periphere arterielle Verschlusskrankheit, Diabetes mellitus, chronisch venöse Insuffizienz. S3 Leitlinie Reg. No. 091-001. 2012.
- Acton C, Barrett S, Beldon P, et al: Best practice statement: the use of topical antiseptic/antimicrobial agents in wound management. Second edition, May 2011. http://www.wounds-uk.com/pdf/content_9969.pdf.
- World Health Organization: Prevention and management of wound infection: guidance from WHO's Department of Violence and Injury Prevention and Disability and the Department of Essential Health Technologies. 2008. http://www.who.int/hac/techguidance/tools/guidelines_prevention_and_management_wound_infection.pdf.
- Kramer A, Assadian O, Below H, Willy C: Wound antiseptics today – an overview; in Willy C (ed): *Antiseptics in Surgery – Update 2013*. Berlin, Lindqvist, 2013, pp 85–111.
- Schlüter B, König W: Microbial pathogenicity and host defense mechanisms: crucial parameters of posttraumatic infections. *Thorac Cardiovasc Surg* 1990;38:339–347.
- Thomson PD: Immunology, microbiology, and the recalcitrant wound. *Ostomy Wound Manage* 2000;46(suppl 1A):77S–82S.
- Roth B, Neuenschwander R, Brill F, et al: Effect of antiseptic irrigation on infection rates of traumatic soft tissue wounds: a longitudinal cohort study. *J Wound Care* 2017;26:1–6.
- Hessam S, Sand M, Georgas D, et al: Microbial profile and antimicrobial susceptibility of bacteria found in inflammatory hidradenitis suppurativa lesions. *Skin Pharmacol Physiol* 2016;29:161–167.
- Richter C, Trojahn C, Hillmann K, et al: Reduction of inflammatory and noninflammatory lesions with topical tyrothricin 0.1% in the treatment of mild to severe acne papulopustulosa: a randomized controlled clinical trial. *Skin Pharmacol Physiol* 2016;29:1–8.
- Wohlrab J, Jost G, Abeck D: Antiseptic efficacy of a low-dosed topical triclosan/chlorhexidine combination therapy in atopic dermatitis. *Skin Pharmacol Appl Skin Physiol* 2007;20:71–76.
- Stelzner A: Bakterielle Zytoadhärenz; in Krasilnikow AP, Kramer A, Gröschel D, Weuffen W (eds): *Handbuch der Antiseptik, Bd. I/4, Faktoren der Mikrobiellen Kolonisation*. Stuttgart, Fischer, 1984, pp 160–217.
- Hentzer M, Riedel K, Rasmussen TB, et al: Inhibition of quorum sensing in *Pseudomonas aeruginosa* biofilm bacteria by a halogenated furanone compound. *Microbiol* 2002;148:87–102.
- König B, Reimer K, Fleischer W, König W: Effects of Betaisodona on parameters of host defense. *Dermatology* 1997;195(suppl 2):42–48.
- Menke H, Pelzer M, Raff T, Siebert J, Germann G: Ein neues lokales Antiseptikum zur Oberflächenbehandlung bei Schwerstverbrannten. *Akt Traumotol* 2001;31:211–215.

- 29 Medina-Tamayo J, Sánchez-Miranda E, Balleza-Tapia H, et al: Super-oxidized solution inhibits IgE-antigen-induced degranulation and cytokine release in mast cells. *Int Immunopharmacol* 2007;7:1013–1024.
- 30 Reimer K, Vogt PM, Brögmann B, et al: An innovative topical drug formulation for wound healing and infectin treatment: in vitro and in vivo investigations of a povidone iodine liposome hydrogel. *Dermatology* 2000; 201:235–241.
- 31 Kramer A, Roth B, Müller G, Rudolph P, Klöcker N: Influence of the antiseptic agents polihexanide and octenidine on FL cells and on healing of experimental superficial aseptic wounds in piglets: a double-blind, randomized, stratified, controlled, parallel group study. *Skin Pharmacol Physiol* 2004;17:141–146.
- 32 Roth C, Beule AG, Kramer A, Hosemann W, Kohlmann T, Scharf C: Response analysis of stimulating efficacy of polihexanide in an in vitro wound model with respiratory ciliary epithelial cells. *Skin Pharmacol Physiol* 2010; 23(suppl 1):35–40.
- 33 Kramer A, Kremer J, Assadian O, et al: The classification of antiseptic products to be administered to wounds – another borderline case between medicinal products and medical devices? *Int J Clin Pharmacol Ther* 2006;44: 677–692.
- 34 Kramer A, Jäkel C, Kremer J, Dähne H, Schwemmer J, Assadian O: Abgrenzung von Arzneimitteln und Medizinprodukten sowie Konsequenzen für den Verbraucherschutz; in Kramer A, Assadian O (eds): *Wahlhäusser Praxis der Sterilisation, Desinfektion, Antiseptik und Konservierung*. Stuttgart, Thieme, 2008, pp 592–600.
- 35 White RJ, Cutting KF: Critical colonization – the concept under scrutiny. *Ostomy Wound Manage* 2006;52:50–56.
- 36 Eisenbeiss W, Siemers F, Amtsberg G, et al: Prospective, double-blinded, randomized controlled trial assessing the effect of an Octenidine-based hydrogel on bacterial colonisation and epithelialization of skin graft wounds in burn patients. *Int J Burns Trauma* 2012;2:71–79.
- 37 Dissemond J, Assadian O, Gerber V, et al: Classification of wounds at risk and their antimicrobial treatment with polyhexanide: a practice-orientated expert recommendation. *Skin Pharmacol Physiol* 2011;24:245–255.
- 38 Pitten FA, Werner HP, Kramer A: A standardized test to assess the impact of different organic challenges on the antimicrobial activity of antiseptics. *J Hosp Inf* 2003;55:108–115.
- 39 Schedler K, Assadian O, Brautferger U, et al: Proposed phase 2/step 2 in-vitro test on basis of EN 14561 for standardised testing of the wound antiseptics PVP-iodine, chlorhexidine digluconate, polihexanide and octenidine dihydrochloride. *BMC Infect Dis* 2017;17:143.
- 40 Hansmann F, Kramer A, Ohgke H, Strobel H, Geerling G: Polyhexamethylbiguanid (PHMB) as preoperative antiseptic for cataract surgery. *Ophthalmol* 2004;101:377–383.
- 41 Hansmann F, Kramer A, Ohgke H, Strobel H, Muller M, Geerling G: Lavasept as an alternative to PVP-iodine as a preoperative antiseptic in ophthalmic surgery. Randomized, controlled, prospective double-blind trial. *Ophthalmol* 2005;102:1043–1050.
- 42 Hoerauf H, Holz FG, Kramer A, Felten N, Krohne T, Behrens-Baumann W: Stellungnahme der Deutschen Ophthalmologischen Gesellschaft, der Retinologischen Gesellschaft und des Berufsverbandes der Augenärzte Deutschlands: Endophthalmitis-Prophylaxe bei intravitrealer operativer Medikamenteneingabe (IVOM). *Klin Monatsbl Augenheilkd* 2013;230:1157–1161.
- 43 Crabtree TD, Pelletier SJ, Pruett TL: Surgical antiseptics; in Block SS (ed): *Disinfection, Sterilization, and Preservation*, ed 5. Philadelphia, Lippincott Williams & Wilkins 2001, pp 919–934.
- 44 Wiegand C, Abel M, Ruth P, Hipler UC: HaCaT keratinocytes in co-culture with *Staphylococcus aureus* can be protected from bacterial damage by polihexanide. *Wound Repair Regen* 2009;17:730–738.
- 45 Lineaweaver W, Howard R, Soucy D, et al: Topical antimicrobial toxicity. *Arch Surg* 1985;120:267–270.
- 46 Cantoni O, Brandi G, Salvaggio L, Cattabeni F: Molecular mechanisms of hydrogen peroxide cytotoxicity. *Ann Ist Super Sanita* 1989; 5:69–73.
- 47 Wilson JR, Mills JG, Prather ID, Dimitrijevic SD: A toxicity index of skin and wound cleansers used on in vitro fibroblasts and keratinocytes. *Adv Skin Wound Care* 2005;18: 37–38.
- 48 Kramer A, Hetmanek R, Weuffen W, et al: Wasserstoffperoxid; in Kramer A, Weuffen W, Krasilnikow AP, et al (eds): *Antibakterielle, Antifungielle und Antivirale Antiseptik – ausgewählte Wirkstoffe*. Handbuch der Antiseptik. Stuttgart, Fischer, 1987, vol II/3, pp 447–491.
- 49 Brudzynski K: Effect of hydrogen peroxide on antibacterial activities of Canadian honeys. *Can J Microbiol* 2006;52:1228–1237.
- 50 Koburger T, Hübner NO, Braun M, Siebert J, Kramer A: Standardized comparison of antiseptic efficacy of triclosan, PVP-iodine, octenidine dihydrochloride, polyhexanide and chlorhexidine digluconate. *J Antimicrob Chemother* 2010;65:1712–1719.
- 51 Müller G, Langer J, Siebert J, Kramer A: residual antimicrobial effect of chlorhexidine digluconate and octenidine dihydrochloride on reconstructed human epidermis. *Skin Pharmacol Physiol* 2014;27:1–8.
- 52 Müller G, Kramer A: Biocompatibility index of antiseptic agents by parallel assessment of antimicrobial activity and cellular cytotoxicity. *J Antimicrob Chemother* 2008;61:1281–1287.
- 53 Marsch G, Mashaqi B, Burgwitz K, et al: Prevention of pacemaker infections with perioperative antimicrobial treatment: an in vitro study. *Europace* 2014;16:604–611.
- 54 Forstner C, Leitgeb J, Schuster R, et al: Bacterial growth kinetics under a novel flexible methacrylate dressing serving as a drug delivery vehicle for antiseptics. *Int J Mol Sci* 2013; 14:10582–10590.
- 55 Junka A, Bartoszewicz M, Smutnicka D, Seczewicz A, Szymczyk P: Efficacy of antiseptics containing povidone-iodine, octenidine dihydrochloride and ethacridine lactate against biofilm formed by *Pseudomonas aeruginosa* and *Staphylococcus aureus* measured with the novel biofilm-oriented antiseptics test. *Int Wound J* 2014;11:730–734.
- 56 Cutting K, Westgate S: The use of cleansing solutions in chronic wounds. *Wound UK* 2012;8:130–133.
- 57 Uygur F, Özyurt M, Evinç R, Hosbul T, Çeliköz B, Haznedaroglu T: Comparison of octenidine dihydrochloride (Octenisept®), polihexanide (Prontosan®) and povidone iodine (Betadine®) for topical antibacterial effects in *Pseudomonas aeruginosa*-contaminated, full-skin thickness burn wounds in rats. *Cent Eur J Med* 2008;3:417–421.
- 58 Hübner NO, Assadian O, Sciermoch K, Kramer A: Interaction of antiseptics and antibiotics – principles and first in vitro results (in German). *GMS Krankenhaushyg Interdiszip* 2007;2:Doc59.
- 59 Hübner NO, Siebert J, Kramer A: Octenidine dihydrochloride, a modern antiseptic for skin, mucous membranes and wounds. *Skin Pharmacol Physiol* 2010;23:244–258.
- 60 Calow T, Oberle K, Bruckner-Tuderman L, Jakob T, Schumann H: Contact dermatitis due to use of Octenisept in wound care. *J Dtsch Dermatol Ges* 2009;7:759–765.
- 61 Stahl J, Braun M, Siebert J, Kietzmann M: The percutaneous permeation of a combination of 0.1% octenidine dihydrochloride and 2% 2-phenoxyethanol (Octenisept®) through skin of different species in vitro. *BMC Vet Res* 2011;7:44.
- 62 Chamanga ET, Hughes M, Hilston K, Sparke A, Jandrisits JM: Chronic wound bed preparation using a cleansing solution. *Br J Nurs* 2015;24:30–36.
- 63 Braun M, McGrath A, Downie F: Octenilin range. *Wounds UK* 2013;9:1–4.
- 64 Braun M, Price J, Ellis M: An evaluation of the efficacy and cost-effectiveness of Octenilin® for chronic wounds. *Wounds UK* 2014;10: 89–96.
- 65 Urbach M, Mügge G: Libysche und syrische Kriegsverletzte – Wundversorgung am Bundeswehrkrankenhaus Hamburg. *WundManagement* 2013;4:51.
- 66 Klein D, Becker D, Urbach M, Mügge G: Versorgung libyscher Kriegsverletzter am Bundeswehrkrankenhaus Hamburg unter spezieller Berücksichtigung der Hygienemassnahmen. *Wehrmed Wehrpharm* 2013;1: 52–54.

- 67 Krasowski G, Wajda R, Olejniczak-Nowakowska M: Economic outcomes of a new chronic wound treatment system in Poland. *EWMA J* 2014;14:7–13.
- 68 Mayr-Kanhäuser S, Kränke B, Aberer W: Efficacy of octenidine dihydrochloride and 2-phenoxyethanol in the topical treatment of inflammatory acne. *Acta Dermatovenerol Alp Pannonica Adriat* 2008;17:139–143.
- 69 Höning HJ: Erfahrungen bei der Anwendung von Octenisept® zur Wundantiseptik. *Hyg Med* 2012;37:360–362.
- 70 Octenisept®: Schwellungen und Gewebeschädigungen nach Spülung tiefer Wunden – weitere Massnahmen zur Risikominimierung. *Bull Arzneimittelsicherheit*, Issue 2, June 2016. http://www.pei.de/SharedDocs/Downloads/vigilanz/bulletin-zur-arzneimittelsicherheit/2016/2-2016.pdf?__blob=publicationFile&v=6.
- 71 Siemers F, Stang FH, von Wild T, et al: Erfahrungen mit der lokalen Anwendung von Octenidin-Spüllösung bei der operativen Versorgung von Handinfektionen. Abstract 52. Congress DGH. <http://www.egms.de/static/en/meetings/dgh2011/11dgh41.shtml>.
- 72 Good H: Charakterisierung der Desinfektionsmittel. Aktuelle Probleme der Chirurgie und Orthopädie. Bern, Huber, 1979, pp 87–96.
- 73 Kramer A, Hübner NO, Assadian O, et al: Polihexanide – perspectives on clinical wound antiseptics. *Skin Pharmacol Physiol* 2010; 23(suppl 1):1–3.
- 74 Roth B, Brill FHH: Polihexanide for wound treatment – how it began. *Skin Pharmacol Physiol* 2010;23(suppl 1):4–6.
- 75 Chhabra RS, Huff JE, Haseman JK, Elwell MR, Peters AC: Carcinogenicity of p-chloroaniline in rats and mice. *Food Chem Toxicol* 1991;29:119–124.
- 76 Below H, Assadian O, Baguhl R, et al: Measurements of chlorhexidine, p-chloroaniline, and p-chloronitrobenzene in saliva after mouth wash before and after operation with 0.2% chlorhexidine digluconate in maxillofacial surgery: a randomised controlled trial. *Br J Oral Maxillofac Surg* 2017;55:150–155.
- 77 Fabry W, Reimer C, Azem T, Aepinus C, Kock HJ, Vahlensieck W: Activity of the antiseptic polyhexanide against methicillin-susceptible and methicillin-resistant *Staphylococcus aureus*. *J Glob Antimicrob Resist* 2013; 1:195–199.
- 78 Dissemond J, Witthoff M, Brauns TC, et al: pH-Wert des Milieus chronischer Wunden. *Hautarzt* 2003;54:959–965.
- 79 Wiegand C, Abel M, Ruth P, et al: pH influence on antibacterial efficacy of common antiseptic substances. *Skin Pharmacol Physiol* 2015;28:147–158.
- 80 Müller G, Koburger T, Jethon FUW, Kramer A: Vergleich der bakterioziden Wirksamkeit und in-vitro-Zytotoxizität von Lavasept® und Prontosan®. *GMS Krankenhaushyg Interdiszip* 2007;2:Doc42.
- 81 López-Rojasa R, Fernández-Cuenca F, Serrano-Rocha L, Pascual A: In vitro activity of a polyhexanide-betaine solution against high-risk clones of multidrug-resistant nosocomial pathogens. *Enferm Infecc Microbiol Clin* 2017;35:12–19.
- 82 Kaehn K: An in-vitro model for comparing the efficiency of wound-rinsing solutions. *J Wound Care* 2009;18:229–234.
- 83 Chindera K, Mahato M, Sharma AK, et al: The antimicrobial polymer PHMB enters cells and selectively condenses bacterial chromosomes. *Sci Rep* 2016;6:23121.
- 84 Kamaruzzaman NF, Firdessa R, Good L: Bactericidal effects of polyhexamethylene biguanide against intracellular *Staphylococcus aureus* EMRSA-15 and USA 300. *J Antimicrob Chemother* 2016;71:1252–1259.
- 85 Kramer A, Assadian O, Pleyer U: Antiinfektive Therapie bei Konjunktivitis und Keratitis; in Pleyer U (eds): *Entzündliche Augenerkrankungen*. Berlin, Springer, 2014, pp 23–33.
- 86 Fabry WH, Kock HJ, Vahlensieck W: Activity of the antiseptic polyhexanide against Gram-negative bacteria. *Microb Drug Resist* 2014; 20:138–143.
- 87 Koburger T, Müller G, Eisenbeiss W, Assadian O, Kramer A: Microbicidal activity of polihexanide. *GMS Krankenhaushyg Interdiszip* 2007;2:Doc44.
- 88 Werthén M, Davoudi M, Sonesson A, et al: *Pseudomonas aeruginosa*-induced infection and degradation of human wound fluid and skin proteins ex vivo are eradicated by a synthetic cationic polymer. *J Antimicrob Chemother* 2004;54:772–779.
- 89 Carpenter S, Davis S, Fitzgerald R, et al: Expert recommendations for optimizing outcomes in the management of biofilm to promote healing of chronic wounds. *Wounds* 2016;28(suppl 6):1–20.
- 90 Hübner NO, Matthes R, Koban I, et al: Efficacy of chlorhexidine, polihexanide and tissue-tolerable plasma against *Pseudomonas aeruginosa* biofilms grown on polystyrene and silicone materials. *Skin Pharmacol Physiol* 2010;34;23(suppl 1):28–34.
- 91 Perez R, Davies SC, Kaehn K: Wirkung verschiedener Wundspüllösungen auf MRSA-Biofilme in Wunden im Tiermodell (Schwein). *WundManagement* 2010;4:44–48.
- 92 Wiegand C, Moritz S, Hessler N, et al: Antimicrobial functionalization of bacterial nanocellulose by loading with polihexanide and povidone-iodine. *J Mater Sci Mater Med* 2015;26:245.
- 93 Fabry W, Kock HJ: In-vitro activity of polyhexanide alone and in combination with antibiotics against *Staphylococcus aureus*. *J Hosp Infect* 2014;86:68–72.
- 94 Hübner NO, Kramer A: Review on the efficacy, safety and clinical applications of polihexanide, a modern wound antiseptic. *Skin Pharmacol Physiol* 2010;23(suppl 1):17–27.
- 95 Roth C, Beule A, Kramer A, Hosemann W, Kohlmann T, Scharf C: Response analysis of stimulating efficacy of polihexanide in an in vitro wound model with respiratory ciliary epithelial cells. *Skin Pharmacol Physiol* 2010;23(suppl 1):35–40.
- 96 Wiegand C, Abel M, Kramer A, Müller G, Ruth P, Hipler UC: Proliferationsförderung und Biokompatibilität von Polihexanid. *GMS Krankenhaushyg Interdiszip* 2007; 2:Doc43.
- 97 Napavichayanun S, Yamdech R, Aramwit P: The safety and efficacy of bacterial nanocellulose wound dressing incorporating sericin and polyhexamethylene biguanide: in vitro, in vivo and clinical studies. *Arch Dermatol Res* 2016;308:123–132.
- 98 Goertz O, Hirsch T, Ring A, et al: Influence of topically applied antimicrobial agents on muscular microcirculation. *Ann Plast Surg* 2011;67:407–412.
- 99 Kramer A, Behrens-Baumann W: Prophylactic use of topical anti-infectives in ophthalmology. *Ophthalmologica* 1997;211:68–76.
- 100 Creppy EE, Diallo A, Moukha S, Eklugadegbeku C, Cros D: Study of epigenetic properties of poly(hexamethylene biguanide) hydrochloride (PHMB). *Int J Environ Res Public Health* 2014;11:8069–8092.
- 101 Kramer A, Eberlein T, Assadian O: Erweiterung zum Beitrag “Polihexanid – Rechtsaspekte einer Risikoeinschätzung” von Volker Grosskopf und Michael Schanz. *WundManagement* 2017;11:32–38.
- 102 Kramer A, Eberlein T, Müller G, Assadian A: Polihexanide – different aspects of a risk assessment. *J Wound Care*, in press.
- 103 Olivieri J, Eigenmann PA, Hauser C: Severe anaphylaxis to a new disinfectant: polyhexanide, a chlorhexidine polymer. *Schweiz Med Wschr* 1998;128:1508–1511.
- 104 Kautz O, Schumann H, Degerbeck F, Venemalm L, Jakob T: Severe anaphylaxis to the antiseptic polyhexanide. *Allergy* 2010;65: 1068–1070.
- 105 Creytens K, Goossens A, Faber M, Ebo D, Aerts O: Contact urticaria syndrome caused by polyaminopropyl biguanide in wipes for intimate hygiene. *Contact Derm* 2014;71: 307–309.
- 106 Schröder MA, Kirketerp-Møller K, Winther L: Suspected anaphylaxis by wound treatment with polyhexanide derivate wound products (in Danish). *Ugeskr Laeger* 2014; 176:V02120094.
- 107 Schnuch A, Geier J, Uter W, Basketter DA, Jowsey IR: The biocide polyhexamethylene biguanide remains an uncommon contact allergen. *Contact Dermatit* 2007;56:235–239.
- 108 Eberlein T, Assadian O: Clinical use of polihexanide on acute and chronic wounds for antiseptics and decontamination. *Skin Pharmacol Physiol* 2010;23(suppl 1):45–51.

- 109 Harati K, Kiefer J, Behr B, Kneser U, Daigeler A: The use of Prontosan® Wound Gel X in partial and full thickness burns requiring split thickness skin grafts – an interim analysis. *Ann Burns Fire Disasters* 2015;27:292–296.
- 110 Shah C: Polyhexamethylene biguanide (PHMB) treated wound dressings and vancomycin-resistant enterococci (VRE). *Managing Infect Control* 2007;7:26–34.
- 111 Kirker K, Fisher S, James G, McGhee D, Shah C: Efficacy of a polyhexamethylene biguanide-containing antimicrobial foam dressing against MRSA relative to standard foam dressing. *Wounds* 2009;21:229–233.
- 112 Jahn B, Wassenaar TM, Stroh A: Integrated MRSA-Management (IMM) with prolonged decolonization treatment after hospital discharge is effective: a single centre, non-randomised open-label trial. *Antimicrob Resist Infect Control* 2016;5:25.
- 113 Daeschlein G, Assadian O, Bruck JC, Meinel C, Kramer A, Koch S: Feasibility and clinical applicability of polyhexanide for treatment of second-degree burn wounds. *Skin Pharmacol Physiol* 2007;20:292–296.
- 114 Moore K, Gray D: Using PHMB antimicrobial to prevent wound infection. *Wounds UK* 2007;3:96–110.
- 115 Butcher M: PHMB: an effective antimicrobial in wound bioburden management. *Br J Nurs* 2012;21:16–21.
- 116 Gilliver S: PHMB: a well-tolerated antiseptic with no reported toxic effects. *J Wound Care* 2009;18(suppl):9–14.
- 117 Cutting KF: Addressing the challenge of wound cleansing in the modern era. *Br J Nurs* 2010;19:1–5.
- 118 Lenselink E, Andriessen A: A cohort study on the efficacy of a polyhexanide-containing biocellulose dressing in the treatment of biofilms in wounds. *J Wound Care* 2011;20:534–539.
- 119 Swan J: Case report of a venous leg ulcer using Suprasorb® X +PHMB. *Wounds UK* 2011;7(suppl 2):17–18.
- 120 Barrett S, Battacharyya M, Butcher M, et al: Consensus document: PHMB and its potential contribution to wound management. *Wounds UK* 2010;6:1–15.
- 121 Mulder GD, Cavorsi JP, Lee DK: Polyhexamethylene biguanide (PHMB): an addendum to current topical antimicrobials. *Wounds* 2007;19:173–182.
- 122 Roth B, Kramer A: Antiseptische Begleittherapie des Ulcus cruris mit Polihexanid. *GMS Krankenhaushyg Interdisziplin* 2009;4:Doc16.
- 123 Eberlein T, Kanis J: Use of a cellulose PHMB dressing in clinical practice. *Int J Lower Extrem Wounds* 2014;10(suppl 3):1–6.
- 124 Hagelstein SM, Ivins N: Treating recalcitrant venous leg ulcers using a PHMB impregnated dressing: a case study evaluation. *Wounds UK* 2013;9:84–90.
- 125 Reitsma AM, Rodeheaver GT: Effectiveness of a New Antimicrobial Gauze Dressing as a Bacterial Barrier. *Mansfield, Tyco Healthcare Group LP*, 2001, pp 1–4.
- 126 Cazzaniga A, Serralta V, Davis S, Orr R, Eaglstein W, Mertz PM: The effect of an antimicrobial gauze dressing impregnated with 0.2-percent polyhexamethylene biguanide as a barrier to prevent *Pseudomonas aeruginosa* wound invasion. *Wounds* 2002;14:169–176.
- 127 Davis S, Mertz PM, Cazzaniga A, Serralta V, Orr R, Eaglstein W: The use of new antimicrobial gauze dressings: effects on the rate of epithelialization of partial-thickness wounds. *Wounds* 2002;14:252–256.
- 128 Hunt S: Case 14: Octenilin wound gel versus betaine/PHMB gel. *J Wound Care* 2016;25(suppl 3):22–23.
- 129 Gentile A, Gerli S, Di Renzo GC: A new non-invasive approach based on polyhexamethylene biguanide increases the regression rate of HPV infection. *BMC Clin Pathol* 2012;12:17.
- 130 Thorn RMS, Lee SWH, Robinson GM, Greenman J, Reynolds DM: Electrochemically activated solutions: evidence for antimicrobial efficacy and applications in healthcare environments. *Eur J Clin Microbiol Infect Dis* 2012;31:641–653.
- 131 Wang L, Bassiri M, Najafi R, et al: Hypochlorous acid as a potential wound care agent. Part I. Stabilized hypochlorous acid: a component of the inorganic armamentarium of innate immunity. *J Burn Wounds* 2007;6:65–79.
- 132 D’Atanasio N, Capezzone de Joannon A, Mangano G, et al: A new acid-oxidizing solution: assessment of its role on methicillin-resistant *Staphylococcus aureus* (MRSA) biofilm morphological changes. *Wounds* 2015;27:265–273.
- 133 Tanaka H, Hirakata Y, Kaku M, Yashida R, Takemura H: Antimicrobial activity of super oxidized water. *J Hosp Infect* 1996;34:43–49.
- 134 Middleton AM, Chadwick MV, Sanderson JL, Gaya H: Comparison of a solution of super oxidized water (sterilox) with glutaraldehyde for the disinfection of bronchoscopes, contaminated. *J Hosp Infect* 2000;45:278–282.
- 135 Tanaka H, Hirakata Y, Kaku M, Yashida R, Takemura H: Antimicrobial activity of super oxidized water. *J Hosp Infect* 1996;34:43–49.
- 136 Aggarwal R, Goel N, Chaudhary U, Kumar V, Ranjan KP: Evaluation of microbiocidal activity of superoxidized water on hospital isolates. *Ind J Pathol Microbiol* 2010;53:757–759.
- 137 Velazquez-Meza ME, Hernández-Salgado M, Sánchez-Alemán MA: Evaluation of the antimicrobial activity of a super oxidized solution in clinical isolates. *Microbial Drug Resistance* 2015;21:367–372.
- 138 Kubota A, Nose K, Yonekura T, Kosumi T, Yamauchi K, Oyanagi H: Effect of electrolyzed strong acid water on peritoneal irrigation of experimental perforated peritonitis. *Surg Today* 2009;39:514–517.
- 139 Gutiérrez AA: The science behind stable, super-oxidized water. *Wounds* 2006;18(suppl):7–10.
- 140 Inagaki H, Shibata Y, Obata T, et al: Effects of slightly acidic electrolysed drinking water on mice. *Lab Anim* 2011;45:283–285.
- 141 Hasegawa R, Takahashi M, Kokubo T, et al: Carcinogenicity study of sodium hypochlorite in F344 rats. *Food Chem Toxicol* 1986;24:1295–1302.
- 142 Kurokawa Y, Takayama S, Konishi Y, et al: Long-term in vivo carcinogenicity tests of potassium bromate, sodium hypochlorite, and sodium chlorite conducted in Japan. *Environ Health Perspect* 1986;69:221–235.
- 143 Ohno H, Higashidate M, Yokosuka T: Mediastinal irrigation with superoxidized water after open-heart surgery: the safety and pitfalls of cardiovascular surgical application. *Surg Today* 2000;30:1055–1056.
- 144 Sekiya S, Ohmori K, Harii K: Treatment of infectious skin defects or ulcers with electrolyzed strong acid aqueous solution. *Artif Organs* 1997;21:32–38.
- 145 Küster I, Kramer A, Bremert T, Langner S, Hosemann W, Beule AG: Eradication of MRSA skull base osteitis by combined treatment with antibiotics and sinonasal irrigation with sodium hypochlorite. *Eur Arch Otorhinolaryngol* 2016;273:1951–1956.
- 146 Bongiovanni CM: Superoxidized water improves wound care outcomes in diabetic patients. *Diabetic Microvasc Compl Today* 2006;3:11–14.
- 147 Tata MD, Kwan KC, Abdul-Razak MR, Paramalingam S, Yeen WC: Adjunctive use of superoxidized solution in chest wall necrotizing soft tissue infection. *Ann Thor Surg* 2009;87:1613–1614.
- 148 Aragón-Sánchez J, Lázaro-Martínez JL, Quintana-Marrero Y, et al: Super-oxidized solution (Dermacyn Wound Care) as adjuvant treatment in the postoperative management of complicated diabetic foot osteomyelitis: preliminary experience in a specialized department. *Int J Low Extrem Wounds* 2013;12:130–137.
- 149 Inoue Y, Endo S, Kondo K, Ito H, Onori H, Sarto K: Trail of electrolyzed strong acid aqueous solution in the treatment of peritonitis and in abscesses. *Artif Organs* 1997;21:28–31.
- 150 Garg PK, Kumar A, Sharda VK, Saini A, Garg A, Sandhu A: Evaluation of intraoperative peritoneal lavage with super-oxidized solution and normal saline in acute peritonitis. *Arch Int Surg* 2013;3:43–48.
- 151 Allie DE: Super-oxidized microcyn technology in lower-extremity wounds. *Wounds* 2006;18(suppl):3–6.

- 152 Wolvos TA: Advanced wound care with stable, super-oxidized water. *Wounds* 2006; 18(suppl):11–13.
- 153 Hierholzer G, Görtz G: PVP-Iod in der operativen Medizin. Berlin, Springer, 1984.
- 154 Capriotti K, Capriotti JA: Topical iodophor preparations: chemistry, microbiology, and clinical utility. *Dermatol Online J* 2012; 18: 11.
- 155 Noda Y, Fujii K, Fujii S: Critical evaluation of cadexomer-iodine ointment and povidone-iodine sugar ointment. *Int J Pharm* 2009;372:85–90.
- 156 Kramer A, Reichwagen S, Heldt P, Widulle H, Nürnberg W: Oxidanzien; in Kramer A, Assadian O (eds): *Wallhäussers Praxis der Sterilisation, Desinfektion, Antiseptik und Konservierung*. Stuttgart, Thieme, 2008, pp 713–745.
- 157 König B, König W, Reimer K: Jod – die Stellung eines alten Desinfektionsmittels in der modernen Infektiologie. *Dtsch Med Wochenschr* 1997;122:141.
- 158 König B, Reimer K, Fleischer W, König W: Effects of Betaisodona on parameters of host defense. *Dermatology* 1997;195(suppl 2): 42–48.
- 159 Fitzgerald DJ, Renick PJ, Forrest EC, et al: Cadexomer iodine provides superior efficacy against bacterial wound biofilms in vitro and in vivo. *Wound Repair Regen* 2016;25: 13–24.
- 160 Phillips PL, Yang Q, Davis S, et al: Antimicrobial dressing efficacy against mature *Pseudomonas aeruginosa* biofilm on porcine skin explants. *Int Wound J* 2015;12:469–483.
- 161 Bolton L, Oleniacz W, Constantine B, et al: Repair and antibacterial effects of topical antiseptic agents in vivo; in Maibach H, Lowe I (eds): *Models in Dermatology*, vol 2. Basel, Karger, 1985 pp 145–158.
- 162 Langer S, Botteck NM, Bosse B, et al: Effect of polyvinylpyrrolidone-iodine liposomal hydrogel on wound microcirculation in SKH1-hr hairless mice. *Eur Surg Res* 2006; 38:27–34.
- 163 Langer S, Sedigh Salakdeh M, Goertz O, Steinau HU, Steintraesser L, Homann HH: The impact of topical antiseptics on skin microcirculation. *Eur J Med Res* 2004;9:449–454.
- 164 Lamme EN, Gustafsson TO, Middelkoop E: Cadexomer iodine shows stimulation of epidermal regeneration in experimental full thickness wounds. *Arch Dermatol Res* 1998; 290:18–24.
- 165 Mertz PM, Davis SC, Brewer LD, Franzen L: Can antimicrobials be effective without impairing wound healing? The evaluation of a cadexomer iodine ointment. *Wounds* 1994; 6:184–193.
- 166 Robert LW: Cadexomer iodine: an effective palliative dressing in chronic critical limb ischemia. *Wounds* 2009;21:1.
- 167 Zhou LH, Nahm WK, Badiavas E, Yufit T, Falanga V: Slow release iodine preparation and wound healing: in vitro effects consistent with lack of in vivo toxicity in human chronic wounds. *Br J Dermatol* 2002;146: 365–374.
- 168 Müller G, Hai DN, Kramer A: Lack of in vitro genotoxicity of povidone-iodine in solution, in ointment or in a liposomal formulation (Repithel®). *Dermatology* 2006(suppl 1):212:94–97.
- 169 Freise J, Kohaus S, Körber A, et al: Contact sensitization in patients with chronic wounds: results of a prospective investigation. *J Eur Acad Dermatol Venereol* 2008;22: 1203–1207.
- 170 Below H, Brauer VFH, Kramer A: Iodresorption bei antiseptischer Anwendung von Iodophoren und Schlussfolgerungen zur Risikobewertung. *GMS Krankenhaushyg Interdiszip* 2007;2:Doc41.
- 171 Angel DE, Morey P, Storer JG, Mwipatayi BP: The great debate over iodine in wound care continues: a review of the literature. *Wound Pract Res* 2008;16:6–21.
- 172 Phillips H, Westerbos SJ, Ubbink DT: Benefit and harm of iodine in wound care: a systematic review. *J Hosp Infect* 2010;76:191–199.
- 173 Müller G, Kramer A: Biocompatibility index of antiseptic agents by parallel assessment of antimicrobial activity and cellular cytotoxicity. *J Antimicrob Chemother* 2008;61:1281–1287.
- 174 Gulati S, Qureshi A, Srivastava A, Kataria K, Kumar P, Ji AB: A prospective randomized study to compare the effectiveness of honey dressing vs. povidone iodine dressing in chronic wound healing. *Ind J Surg* 2014;76: 193–198.
- 175 Campbell N, Campbell D: Evaluation of a non-adherent, povidone-iodine dressing in a case series of chronic wounds. *J Wound Care* 2013;22:401–406.
- 176 Oliveira AS, Santos VL: Topical iodophor use in chronic wounds: a literature review. *Rev Latino Enfermagem* 2007;15:671–676.
- 177 Skripitz R, Werner HP: Bakterizide Langzeit-Wirkung ausgewählter Antiseptika. *Hyg Med* 1994;17:19.
- 178 Bedrosian I, Sofia RD, Wolff SM, Dinarello CA: Taurolidine, an analogue of the amino acid taurine, suppresses interleukin 1 and tumor necrosis factor synthesis in human peripheral blood mononuclear cells. *Cytokine* 1991;3:568.
- 179 Rosman C, Westerveld GJ, van Oeveren W, Kooi K, Bleichrodt RP: Effect of intraperitoneal antimicrobials on the concentration of bacteria, endotoxin, and tumor necrosis factor in abdominal fluid and plasma in rats. *Eur Surg Res* 1996;28:351.
- 180 Akkuş A, Gülmen M, Cevik A, et al: Effect of peritoneal lavage with taurolidine on primary colonic anastomosis in a rat model of secondary peritonitis. *Surg Today* 2006;36: 436–440.
- 181 Kramer A, Halle W, Adrian V, et al: Antimikrobielle Wirkung, Zytotoxizität und Phytotoxizität als Basisinformation zur Verträglichkeitsprüfung von Desinfektionsmitteln bzw. Antiseptika. *Z Ges Hyg* 1987;33: 610–615.
- 182 Kramer A, Adrian V, Rudolph P, Wurster S, Lippert H: Explantationstest mit Haut und Peritoneum der neonatalen Ratte als Voraussagetest zur Verträglichkeit lokaler Antinfektiva für Wunden und Körperhöhlen. *Chirurgie* 1998;69:840–845.
- 183 Simpson JM, Séguin B, Gitelman A: Effects of topical application of taurolidine on second intention healing of experimentally induced wounds in rats. *Am J Vet Res* 2008;69: 1210–1216.
- 184 Baker M, Jones JA, Nguyen-Van-Tam JS, et al: Taurolidine peritoneal lavage as prophylaxis against infection after elective colorectal surgery. *Br J Surg* 1994;1:1054–1056.
- 185 Willatts SM, Radford S, Leitermann M: Effect of the antiendotoxic agent, taurolidine, in the treatment of sepsis syndrome: a placebo-controlled, double-blind trial. *Crit Care Med* 1995;23:1033–1039.
- 186 Gallieni M, Chiarelli G, Olivi L, Cozzolino M, Cusi D: Unsuccessful application of taurolidine in the treatment of fungal peritonitis in peritoneal dialysis. *Clin Nephrol* 2011; 75:70–73.
- 187 Schneider A, Sack U, Rothe K, Bennek J: Peritoneal taurolidine lavage in children with localised peritonitis due to appendicitis. *Pediatr Surg Int* 2005;21:445–448.
- 188 Baker DM, Jones JA, Nguyen-Van-Tam JS, et al: Taurolidine peritoneal lavage as prophylaxis against infection after elective colorectal surgery. *Br J Surg* 1994;81:1054–1056.
- 189 Hübner-Müller C, Peter RU: Taurolin in der Lokalbehandlung septischer Ulcera. *Z Wundbehandl* 2000;12:7–9.
- 190 Dissemond J, Böttrich JG, Braunwarth H, Hilt J, Wilken P, Münter KC: Evidenz von Silber in der Wundbehandlung – Meta-Analyse der klinischen Studien von 2000–2015. *J Dtsch Dermatol Ges* 2017;15:524–536.
- 191 Vermeulen H, van Hattem JM, Storm-Versloot MN, Ubbink DT: Topical silver for treating infected wounds. *Cochrane Database Syst Rev* 2007;24:CD005486.
- 192 Storm-Versloot MN, Vos CG, Ubbink DT, Vermeulen H: Topical silver for preventing wound infection. *Cochrane Database Syst Rev* 2010;17:CD006478.
- 193 FDA Drug Safety Communication: FDA warns about rare but serious allergic reactions with the skin antiseptic chlorhexidine gluconate. 2017. <https://www.fda.gov/Drugs/DrugSafety/ucm530975.htm>.

- 194 Kramer A, Daeschlein G, Kammerlander G, et al: Konsensusempfehlung zur Auswahl von Wirkstoffen für die Wundantiseptik. *Z Wundheilung* 2004;3:110–120.
- 195 Kramer A, Reichwagen S, Widulle H, Heldt P: 8-Chinolinole; in Kramer A, Assadian O (eds): *Wallhäusers Praxis der Sterilisation, Desinfektion, Antiseptik und Konservierung*. Stuttgart, Thieme, 2008 pp 823–826.
- 196 Kramer A, Reichwagen S, Widulle H, Heldt P: Nitrofurane; in Kramer A, Assadian O (eds): *Wallhäusers Praxis der Sterilisation, Desinfektion, Antiseptik und Konservierung*. Stuttgart, Thieme, 2008, pp 836–838.
- 197 Wound Healing and Management Node Group: Evidence summary: polyhexamethylene biguanide (PHMB) wound dressings. *Wound Pract Res* 2013;21:82–85.
- 198 Vogt PM, Hauser J, Rossbach O, et al: Polyvinyl pyrrolidone-iodine liposome hydrogel improves epithelialization by combining moisture and antiseptics: a new concept in wound therapy. *Wound Repair Regen* 2001; 9:116–122.
- 199 Kramer A, Assadian O, Frank M, Bender C, Hinz P: Prevention of post-operative infections after surgical treatment of bite wounds. *GMS Krankenhaushyg Interdiszip* 2010;5: Doc12.
- 200 Hinz P, Boenigk I, Ekkernkamp A, Wolf A, Kramer A: Prinzipien der chirurgischen Wundbehandlung. *Gynäkol Prax* 2011;35: 711–719.
- 201 Gerber V: Phasengerechte, problemorientierte Wundversorgung. *GMS Krankenhaushyg Interdiszip* 2006;1:Doc29.
- 202 AWMF: Anforderungen der Hygiene bei chronischen und sekundär heilenden Wunden. AWMF Leitlinien Register No. 029/042. 2014. http://www.awmf.org/uploads/tx_szleitlinien/029-042l_S1_Chronische_Wunden_Hygieneanforderungen_2014-01.pdf.
- 203 Rothe K, Tsokos M, Handrick W: Tier- und Menschenbissverletzungen. *Dtsch Arztebl Int* 2015;112:433–443.
- 204 Eisenbeiss W: Therapie der infizierten Verbrennungswunde. *GMS Krankenhaushyg Interdiszip* 2006;1:Doc26.
- 205 Habild G, Bruck JC: Primärversorgung von Verbrennungswunden. *GMS Krankenhaushyg Interdiszip* 2006;1:Doc25.
- 206 Blangy H, Simon D, Levy-Cloez A, et al: Topic silver sulfadiazine bicytopenia: first case. *Therapie* 2002;57:307–309.
- 207 Fisher NM, Marsh E, Lazova R: Scar-localized argyria secondary to silver sulfadiazine cream. *J Am Acad Dermatol* 2003;49:730–732.
- 208 Mueller TC, Loos M, Haller B, et al: Intraoperative wound irrigation to reduce surgical site infections after abdominal surgery: a systematic review and meta-analysis. *Langenbecks Arch Surg* 2015;400:167–181.
- 209 Hübner NO, Wander K, Ryll S, Kramer A: Successful decolonisation of MRSA-positive patients. *Med Monatsschr Pharm* 2009;32: 87–94.
- 210 Rode H, Hanslo D, de Wet PM, Millar AJ, Cywes S: Efficacy of mupirocin in methicillin-resistant *Staphylococcus aureus* burn wound infection. *Antimicrob Agents Chemother* 1989;33:1358–1361.
- 211 Kauffman CA, Terpenning MS, He X, et al: Attempts to eradicate methicillin-resistant *Staphylococcus aureus* from a long-term care facility with the use of mupirocin ointment. *Am J Med* 1993;94:371–378.
- 212 Kampf G, Kramer A: Eradication of methicillin-resistant *Staphylococcus aureus* with an antiseptic soap and nasal mupirocin among colonized patients – an open uncontrolled clinical trial. *Ann Clin Microbiol Antimicrob* 2004;3:9.
- 213 Kim PJ, Attinger CE, Olawoye O, et al: Negative-pressure wound therapy with instillation: international consensus guidelines. *Plast Reconstr Surg* 2013;132:1569–1579.
- 214 Wolvos T: The evolution of negative pressure wound therapy: negative pressure wound therapy with instillation. *J Wound Care* 2015;24(suppl 4):15–20.
- 215 Huang C, Leavitt T, Bayer LR, Orgill DP: Effect of negative pressure wound therapy on wound healing. *Curr Probl Surg* 2014;51: 301–331.
- 216 Fleischmann W: Die V.A.C.-Instill zur Behandlung der akuten Wundinfektion. *GMS Krankenhaushyg Interdiszip* 2006;1:Doc28.
- 217 Fleischmann W, Russ M, Westhauser A, Stampehl M: Vacuum sealing as carrier system for controlled local drug administration in wound infection. *Unfallchir* 1998;101: 649–654.
- 218 Kim PJ, Attinger CE, Olawoye O, et al: Negative pressure wound therapy with instillation: review of evidence and recommendations. *Wounds* 2015;27:2–19.
- 219 Timmers MS, Le Cessie S, Banwell P, Jukema GN: The effects of varying degrees of pressure delivered by negative-pressure wound therapy on skin perfusion. *Ann Plast Surg* 2005;55:665–671.
- 220 Davis K, Bills J, Barker J, Kim P, Lavery L: Simultaneous irrigation and negative pressure wound therapy enhances wound healing and reduces wound bioburden in a porcine model. *Wound Repair Regen* 2013;21: 869–875.
- 221 Kim PJ, Attinger CE, Steinberg JS, et al: The impact of negative-pressure wound therapy with instillation compared with standard negative-pressure wound therapy: a retrospective, historical, cohort, controlled study. *Plast Reconstr Surg* 2014;133:709–716.
- 222 Matiassek J, Diomig K, Assadian O: Comparison of the effect of negative pressure wound therapy with different antiseptic dressings on Gr+ and Gr– bacteria in experimental in vitro wounds. *Ger Med Sci* 2015, DOI: 10.3205/15dgprra048.
- 223 Matiassek J, Djedovic G, Unger L, et al: Outcomes for split-thickness skin transplantation in high-risk patients using octenidine. *J Wound Care* 2015;24(suppl 6):8–12.
- 224 Matiassek J, Djedovic G, Mattesich M, et al: The combined use of NPWT and instillation using an octenidine based wound rinsing solution: a case study. *J Wound Care* 2014;23: 590–596.
- 225 Willy C, Scheuermann-Poley C, Stichling M, Stein von T, Kramer A: Importance of wound irrigation solutions and fluids with antiseptic effects in therapy and prophylaxis. Update 2017 (in German). *Unfallchirurg* 2017;120:549–560.
- 226 Nagoba BS, Selkar SP, Wadher BJ, et al: Acidic environment and wound healing: a review. *Wounds* 2015;27:5–11.
- 227 Taylor K: Treatment of *Bacillus pyocyaneus* infection. *J Am Med Assoc* 1916;67:1598–1599.
- 228 Juma IM, Yass HS, Al-Jaberi FH: Comparison between the effect of acetic acid and salicylic acid in different concentrations on *Pseudomonas aeruginosa* isolated from burn wound infection. *Al Taqani* 2007;20:73–78.
- 229 Kramer A, Reichwagen S, Widulle H, Nürnberg W, Heldt P: *Organische Carbonsäuren*; in Kramer A, Assadian O (eds): *Wallhäusers Praxis der Sterilisation*. Stuttgart, Thieme, 2008.
- 230 Madhusudhan VL: Efficacy of 1% acetic acid in the treatment of chronic wounds infected with *Pseudomonas aeruginosa*: prospective randomised controlled clinical trial. *Int Wound J* 2016;13:1129–1136.
- 231 Halstead FD, Rauf M, Moiemens NS, et al: The antibacterial activity of acetic acid against biofilm-producing pathogens of relevance to burns patients. *PLoS One* 2015;10: 0136190.
- 232 McKenna PJ, Lehr GS, Leist P, Welling RE: Antiseptic effectiveness with fibroblast preservation. *Ann Plast Surg* 1991;27:265–268.
- 233 Ryssel H, Kloeters O, Germann G, Schafer T, Wiedemann G, Oehlbauer M: The antimicrobial effect of acetic acid-an alternative to common local antiseptics? *Burns* 2009;35: 695–700.
- 234 Gruber RP, Vistnes L, Pardoe R: The effect of commonly used antiseptics on wound healing. *Plast Reconstr Surg* 1975;55:472–476.
- 235 Sloss JM, Cumberland N, Milner SM: Acetic acid used for the elimination of *Pseudomonas aeruginosa* from burn and soft tissue wounds. *J R Army Med Corp* 1993;139:49–51.
- 236 Nagoba B, Wadher B, Kulkarni P, Kolhe S: Acetic acid treatment of pseudomonal wound infections. *Eur J Gen Med* 2008;5: 104–106.
- 237 Milner SM: Acetic acid to treat *Pseudomonas aeruginosa* in superficial wounds and burns. *Lancet* 1992;340:61.
- 238 Phillips I, Lobo AZ, Fernandes R, Gundara NS: Acetic acid in the treatment of superficial wounds infected by *Pseudomonas aeruginosa*. *Lancet* 1968;1:11–14.

- 239 Salati S, Rather A: Management of pseudo-monal wound infection. *Internet J Surg* 2008;20:1–4.
- 240 Jeong HS, Lee BH, Lee HK, Kim HS, Moon MS, Suh IS: Negative pressure wound therapy of chronically infected wounds using 1% acetic acid irrigation. *Arch Plast Surg* 2015; 42:59–67.
- 241 Hammann A, Huebner NO, Bender C, et al: Antiseptic efficacy and tolerance of tissue-tolerable plasma compared with two wound antiseptics on artificially bacterially contaminated eyes from commercially slaughtered pigs. *Skin Pharmacol Physiol* 2010;23:328–332.
- 242 Hübner NO, Matthes R, Koban I, et al: Efficacy of chlorhexidine, polihexanide and tissue-tolerable plasma against *Pseudomonas aeruginosa* biofilms grown on polystyrene and silicone materials. *Skin Pharmacol Physiol* 2010;23(suppl):28–34.
- 243 Lademann J, Richter H, Schanzer S, et al: Comparison of the antiseptic efficacy of tissue-tolerable plasma and an octenidine hydrochloride-based wound antiseptic on human skin. *Skin Pharmacol Physiol* 2012;25: 100–106.
- 244 Shimizu T, Zimmermann JL, Morfill GE: The bactericidal effect of surface microdischarge plasma under different ambient conditions. *New J Phys* 2011;13:023026.
- 245 Bender C, Hübner NO, Weltmann KD, Scharf C, Kramer A: Tissue tolerable plasma and polihexanide: are synergistic effects possible to promote healing of chronic wounds? In vivo and in vitro results; in Machala Z, Hensel K, Akishev Y (eds): *Plasma for Bio-Decontamination, Medicine and Food Security*. NATO Science for Peace and Security Series A: Chemistry and Biology. Dordrecht, Springer, 2012, pp 312–314.
- 246 Isbary G, Morfill G, Schmidt HU, et al: A first prospective randomized controlled trial to decrease bacterial load using cold atmospheric argon plasma on chronic wounds in patients. *Br J Dermatol* 2010;163:78–82.
- 247 Kramer A, Lademann J, Bender C, et al: Suitability of tissue tolerable plasmas (TTP) for the management of chronic wounds. *Clin Plasma Med* 2013;1:11–18.
- 248 Kramer A, Bekeschus S, Matthes R, et al: Cold physical plasmas in the field of hygiene – relevance, significance, and future applications. *Plasma Proc Polym* 2015;12: 1410–1422.
- 249 Ulrich C, Kluschke F, Patzelt A, et al: Clinical use of cold atmospheric pressure argon plasma in chronic leg ulcers: a pilot study. *J Wound Care* 2015;24:196–203.
- 250 Partecke LI, Evert K, Haugk J, et al: Tissue tolerable plasma (TTP) induce apoptosis in the human pancreatic cancer cell line Colo-357 in vitro and in vivo. *BMC Cancer* 2012; 12:473.
- 251 Fricke K, Koban I, Tresp H, et al: Atmospheric pressure plasma: a high-performance tool for the efficient removal of biofilms. *PLoS One* 2012;7:42539.
- 252 Koban I, Holtfreter B, Hübner NO, et al: Antimicrobial efficacy of non-thermal plasma in comparison to chlorhexidine against dental biofilms on titanium discs in vitro – proof of principle experiment. *J Clin Periodontol* 2011;38:956–965.
- 253 Laroussi M, Kong MG, Morfill G: *Plasma Medicine. Applications of Low-Temperature Gas Plasmas in Medicine and Biology*. Cambridge, Cambridge University Press, 2012.
- 254 Kramer A, Hübner NO, Weltmann KD, et al: Polypragmasia in the therapy of infected wounds – conclusions drawn from the perspectives of low temperature plasma technology for plasma wound therapy. *GMS Krankenhaushyg Interdisziplinär* 2008;3:Doc13.
- 255 Kramer A, Hübner NO, Assadian O, et al: Chancen und Perspektiven der Plasmamedizin durch Anwendung von gewebekompatiblen Atmosphärendruckplasmen (Tissue Tolerable Plasmas, TTP). *GMS Krankenhaushyg Interdisziplinär* 2009;4:Doc10.
- 256 Wiegand C, Fink S, Beier O, et al: Dose- and time-dependent cellular effects of cold atmospheric pressure plasma evaluated in 3D skin models. *Skin Pharmacol Physiol* 2016; 29:257–265.
- 257 Matthes R, Lührman A, Holtfreter S, et al: Antibacterial activity of cold atmospheric pressure argon plasma against 78 genetically different (meca, luk-p, agr or capsular polysaccharide type) *Staphylococcus aureus* strains. *Skin Pharmacol Physiol* 2016;29:83–91.
- 258 Kramer A, Schauer F, Papke R, et al: Plasma application for hygienic purposes in medicine, industry, and biotechnology – update 2017; in Metelmann HR, Woedtke von T, Weltmann KD (eds): *Comprehensive Clinical Plasma Medicine – Cold Physical Plasma for Medical Application*. Berlin, Springer, 2018.
- 259 Wiegand C, Beier O, Horn K, et al: Antimicrobial impact of cold atmospheric pressure plasma on medical critical yeasts and bacteria cultures. *Skin Pharmacol Physiol* 2014; 27:25–35.
- 260 Lademann O, Kramer A, Richter H, et al: Skin disinfection by plasma-tissue interaction: comparison of the effectivity of tissue-tolerable plasma and a standard antiseptic. *Skin Pharmacol Physiol* 2011;24:284–288.
- 261 Wiegand C, Fink S, Hipler UC, Beier O, Horn K, Pfuch A, Schimanski A, Grünler B: Cold atmospheric pressure plasmas exhibit antimicrobial properties against critical bacteria and yeast species. *J Wound Care* 2017; 26:462–468.
- 262 Bender C, Partecke LI, Kindel E, et al: The modified HET-CAM as a model for the assessment of the inflammatory response to tissue tolerable plasma. *Toxicol In Vitro* 2011;25:530–537.
- 263 Bender C, Pavlovic D, Wegner A, et al: Intravital fluorescence microscopy for the assessment of microcirculation and leucocyte-endothel interaction after application of tissue tolerable plasma in the HET-CAM; in Mikikian M, Rabat H, Robert E, Pouvesle JM (eds): *Book of Abstracts: 4th International Conference on Plasma Medicine*. Greifswald, ISPM, 2012.
- 264 Kluge S, Bekeschus S, Bender C, et al: Investigating the in vivo mutagenicity of a cold atmospheric pressure argon plasma jet in an HET-MN model. *PLoS One* 2016;11: 0160667.
- 265 Bender C, Kramer A: Behandlung von Wundheilungsstörungen beim Haustier mit kaltem Atmosphärendruckplasma. *Tierärztl Umschau* 2016;71:262–268.
- 266 Assadian O, Ousey K, Daeschlein G, et al: Effects and safety of atmospheric low temperature plasma on bacterial reduction in chronic wounds and wound size reduction – a systematic review and meta-analysis. *Br J Derm*, in press.
- 267 Horton JW: Free radicals and lipid peroxidation mediated injury in burn trauma: the role of antioxidant therapy. *Toxicology* 2003;189:75–88.
- 268 Beldame J, Lagrave B, Lievain L, Lefebvre B, Frebourg N, Dujardin F: Surgical glove bacterial contamination and perforation during total hip arthroplasty implantation: when gloves should be changed. *Orthop Traumatol Surg Res* 2012;98:432–440.
- 269 Neu HC, Fu KP: Cefuroxime, a beta-lactamase-resistant cephalosporin with a broad spectrum of gram-positive and -negative activity. *Antimicrob Agents Chemother* 1978; 13:657–664.
- 270 Andrews JM: Determination of minimum inhibitory concentrations. *J Antimicrob Chemother* 2001;48(suppl 1):5–16.
- 271 Bowler PG, Duerden BI, Armstrong DG: Wound microbiology and associated approaches to wound management. *Clin Microbiol Rev* 2001;14:244–269.
- 272 Ebert M, Assadian O, Hübner NO, Koburger T, Kramer A: Antimicrobial efficacy of the silver wound dressing Biatain Ag in a disc carrier test simulating wound secretion. *Skin Pharmacol Physiol* 2011;24:337–341.
- 273 Maitre S, Jaber K, Perrot JL, Guy C, Cambazard F: Increased serum and urinary levels of silver during treatment with topical silver sulfadiazine. *Ann Dermatol Venerol* 2002; 129:217–219.
- 274 Drosou A, Falabella A, Kirsner RS: Antiseptics on wounds: an area of controversy. *Wounds* 2003;15:49–166.

- 275 Nagoba BS, Selkar SP, Wadher BJ, Gandhi RC: Acetic acid treatment of pseudomonal wound infections – a review. *J Infect Public Health* 2013;6:410–415.
- 276 Bolton L, Oleniacz W, Constantine B, et al: Repair and antibacterial effects of topical antiseptic agents in vivo; in Maibach H, Lowe I (eds): *Models in Dermatology*, vol 2. Basel, Karger, 1985, pp 145–158.
- 277 Landa-Solis C, González-Espinosa D, Guzmán-Soriano B, et al: Microcyn: a novel super-oxidized water with neutral pH and disinfectant activity. *J Hosp Infect* 2005;61:291–299.
- 278 Hadi SF, Khaliq T, Bilal N, et al: Treating infected diabetic wounds with superoxidized water as antiseptic agent: a preliminary experience. *J Coll Physicians Surg Pak* 2007;17:740–743.
- 279 Müller G, Kramer A: Effect of selected wound antiseptics on adult articular cartilage (bovine sesamoid bone) in the presence of *Escherichia coli* and *Staphylococcus aureus*. *J Orthop Res* 2005;23:127–133.
- 280 Hämmerle G, Strohal R: Efficacy and cost-effectiveness of octenidine wound gel in the treatment of chronic venous leg ulcers in comparison to modern wound dressings. *Int Wound J* 2016;13:182–188.
- 281 Krasowski G, Jawień A, Tukiendorf A, et al: A comparison of an antibacterial sandwich dressing vs dressing containing silver. *Wound Repair Regen* 2015;23:525–530.
- 282 Sopata M, Tomaszewska E, Muszyński Z, Ciupińska M, Kotlińska-Lemieszek A: The pilot study assessing efficacy and versatility of novel therapy for neoplastic ulceration: clinical and microbiological aspects. *Postepy Dermatol Alergo* 2013;30:237–245.
- 283 Vanscheidt W, Harding K, Téot L, Siebert J: Effectiveness and tissue compatibility of a 12-week treatment of chronic venous leg ulcers with an octenidine based antiseptic – a randomized, double-blind controlled study. *Int Wound J* 2012;9:316–323.
- 284 Radu CA, Gazyakan E, Germann G, Riedel K, Reichenberger M, Ryssel H: Optimizing Suprathel®-therapy by the use of Octenidine-Gel®. *Burns* 2011;37:294–298.
- 285 Krzeminski M, Bartoszewicz M, Czarniak E, Gregorowicz-Warpas D, Mączyńska B, Junka A: The use of octenidine dihydrochloride in the treatment of musculoskeletal infections. *Adv Clin Exp Med* 2010;19:631–636.
- 286 Sopata M, Ciupinska M, Glowacka A, Muszyński Z, Tomaszewska E: Effect of octenisept antiseptic on bioburden of neoplastic ulcers in patients with advanced cancer. *J Wound Care* 2008;17:24–27.
- 287 Bellingeri A, Falciani F, Trapedini P, et al: Effect of a wound cleansing solution on wound bed preparation and inflammation in chronic wounds: a single-blind RCT. *J Wound Care* 2016;25:160–168.
- 288 Ceviker K, Canikoğlu M, Tatloğlu S, Bağdatlı Y: Reducing the pathogen burden and promoting healing with polyhexanide in non-healing wounds: a prospective study. *J Wound Care* 2015;24:582–586.
- 289 Durante CM, Greco A, Sidoli O, Maino C, Gallarini A, Ciprandi G: Evaluation of the effectiveness of a polyhexanide and propyl betaine-based gel in the treatment of chronic wounds. *Minerva Chir* 2014;69:283–292.
- 290 Mendes J, Martinho A: An observational study about the performance of a wound gel for the treatment of burn wounds. *EWMA 2014*, poster EP436. <http://de.slideshare.net/EWMA/ewma-2014-ep436-an-observational-study-about-the-performance-of-a-wound-gel-for-the-treatment-of-burn-wounds>.
- 291 Marquardt C, Koppes P, Krohs U, Mares A, Paglinawan R, Höfer D, Schiedeck T: Vakuumtherapie mit PHMB Gaze zur Behandlung postoperativer subkutaner Bauchdeckeninfektionen. *Coloproctology* 2014;36:364–369.
- 292 Gaspard F, Brassard P, Alamet T, et al: Impact of an antimicrobial dressing in reducing surgical site infections in cardiac surgery patients. *Wounds* 2013;25:178–185.
- 293 Eberlein T, Haemmerle G, Signer M, et al: Comparison of PHMB-containing dressing and silver dressings in patients with critically colonised or locally infected wounds. *J Wound Care* 2012;21:12–20.
- 294 Lee CK, Chua YP, Saw A: Antimicrobial gauze as a dressing reduces pin site infection: a randomized controlled trial. *Clin Orthop Relat Res* 2012;470:610–615.
- 295 Sibbald RG, Coutts P, Woo KY: Reduction of bacterial burden and pain in chronic wounds using a new polyhexamethylene biguanide antimicrobial foam dressing: clinical trial results. *Adv Skin Wound Care* 2011;24:78–84.
- 296 Piatkowski A, Drummer N, Andriessen A, Ulrich D, Pallua N: Randomized controlled single center study comparing a polyhexanide containing biocellulose dressing with silver sulfadiazine cream in partial-thickness dermal burns. *Burns* 2011;37:800–804.
- 297 Muangman P, Nitimonton S, Aramwit P: Comparative clinical study of bactigras and Telfa AMD for skin graft donor-site dressing. *Int J Mol Sci* 2011;12:5031–5038.
- 298 Lehner B, Fleischmann W, Becker R, Jukema GN: First experiences with negative pressure wound therapy and instillation in the treatment of infected orthopaedic implants: a clinical observational study. *Int Orthop* 2011;35:1415–1420.
- 299 Romanelli M, Dini V, Barbanera S, Bertone MS: Evaluation of the efficacy and tolerability of a solution containing propyl betaine and polyhexanide for wound irrigation. *Skin Pharmacol Physiol* 2010;23(suppl 1):41–44.
- 300 Mueller SW, Krebsbach LE: Impact of an antimicrobial-impregnated gauze dressing on surgical site infections including methicillin-resistant *Staphylococcus aureus* infections. *Am J Infect Control* 2008;36:651–655.
- 301 Valenzuela A, Perucho N: The effectiveness of a 0.1% polyhexanide gel. *Rev Endferm* 2008;31:7–12.
- 302 Fabry W, Trampenau C, Bettag C, et al: Bacterial decontamination of surgical wounds treated with Lavasept. *Int J Hyg Environ Health* 2006;209:567–573.
- 303 Motta GJ, Milne CT, Corbett LQ: Impact of antimicrobial gauze on bacterial colonies in wounds that require packing. *Ostomy Wound Manage* 2004;50:48–62.
- 304 Kapur V, Marwaha AK: Evaluation of effect and comparison of superoxidised solution (Oxum) v/s povidone iodine (Betadine). *Indian J Surg* 2011;73:48–53.
- 305 Pandey PK, Kousharia M, Shukla S, Das S: Outcomes of superoxide solution dressings in surgical wounds: a randomized case control trial. *Int J Biol Med Res* 2011;2:965–968.
- 306 Piaggese A, Goretti C, Mazzurco S, et al: A randomized controlled trial to examine the efficacy and safety of a new super-oxidized solution for the management of wide post-surgical lesions of the diabetic foot. *Int J Lower Extr Wounds* 2010;9:10–15.
- 307 Abhyankar SV, Venkatesh V, Karnad S, et al: Efficacy and safety of oxum in treatment of chronic wounds. *J Indian Med Assoc* 2009;107:904–906.
- 308 Martinez-De Jesu's FR, Ramos-De la Medina A, Remes-Troche JM, et al: Efficacy and safety of neutral pH superoxidised solution in severe diabetic foot infections. *Int Wound J* 2007;4:353–362.
- 309 Dalla Paola L, Brocco E, Senesi A, Ninkovic S, Merico M, De Vido D: Use of Dermacyn, a new antiseptic agent for the local treatment of diabetic foot ulcers. *J Wound Heal* 2005;2:201.
- 310 Altamirano MA, Preciado MD, Chavez Velarde TJ: Treatment of 2nd and 3rd degree burns in 64 pediatric patients without routine antibiotics using new “super-oxidized solution technology.” Texas Surgical Society Congress, San Antonio, April 1–3, 2005, and European Burns Association Meeting, Estoril, 2005.
- 311 Nanashimah A, Yamaguchit H, Sawai T, et al: Treatment of surgical site infection with aqua oxidation water: comparison with povidone iodine. *Acta Medica Nnagasakiensis* 2001;46:33–37.
- 312 Nherera LM, Woodmansey E, Trueman P, Gibbons GW: Estimating the clinical outcomes and cost differences between standard care with and without cadexomer iodine in the management of chronic venous leg ulcers using a Markov model. *Ostomy Wound Manage* 2016;62:26–40.

- 313 Norman G, Dumville JC, Moore ZEH, Tanner J, Christie J, Goto S: Antibiotics and antiseptics for pressure ulcers. *Cochrane Database Syst Rev* 2016;4:CD011586.
- 314 O'Meara S, Al-Kurdi D, Ologun Y, Ovington LG, Martyn-St JM, Richardson R: Antibiotics and antiseptics for venous leg ulcers. *Cochrane Database Syst Rev* 2014;1:CD003557.
- 315 Singh S, Apte A: Comparative study of silver foam dressing over povidone iodine dressing in infected wounds. *J Evol Med Dental Sci* 2014;3:6233–6242.
- 316 Li SH, Wang Y, Gao HB, Zhao K, Hou YC, Sun W: Experimental study on the toxicity of povidone-iodine solution in brain tissues of rabbits. *Int J Clin Exp Med* 2015;8:14863–14870.
- 317 Kim PJ, Attinger CE, Oliver N, et al: Comparison of outcomes for normal saline and an antiseptic solution for negative-pressure wound therapy with instillation. *Plast Reconstr Surg* 2015;136:657–664.
- 318 Tuncel U, Erkormaz Ü, Turan A: Clinical evaluation of gauze-based negative pressure wound therapy in challenging wounds. *Int Wound J* 2013;10:152–158.
- 319 Goss SG, Schwartz JA, Facchin F, Avdagic E, Gendics C, Lantis JC: Negative pressure wound therapy with instillation (NPTWi) better reduces post-debridement bioburden in chronically infected lower extremity wounds than NPWT alone. *Am Coll Clin Wound Spec* 2012;4:74–80.
- 320 Timmers MS, Graafland N, Bernards AT, Nelissen RG, van Dissel JT, Jukema GN: Negative pressure wound treatment with polyvinyl alcohol foam and polyhexanide antiseptic solution instillation in posttraumatic osteomyelitis. *Wound Repair Regen* 2009;17:278–286.
- 321 Hansson C, Faergemann J: The effect of antiseptic solutions on microorganisms in venous leg ulcers. *Acta Derm Venereol* 1995;75:31–33.
- 322 Klasinc R, Augustin LA, Below H, et al: Evaluation of three experimental in vitro models for the assessment of the mechanical cleansing efficacy of wound irrigation solutions. *Int Wound J* 2017, Epub ahead of print.
- 323 Harnoss JC, Elrub QMH, Koburger T, et al: Irritative potency of selected wound antiseptics in the hen's egg test on chorioallantoic membrane (het cam) to predict their compatibility to wounds. *Wound Repair Regen*, in press.